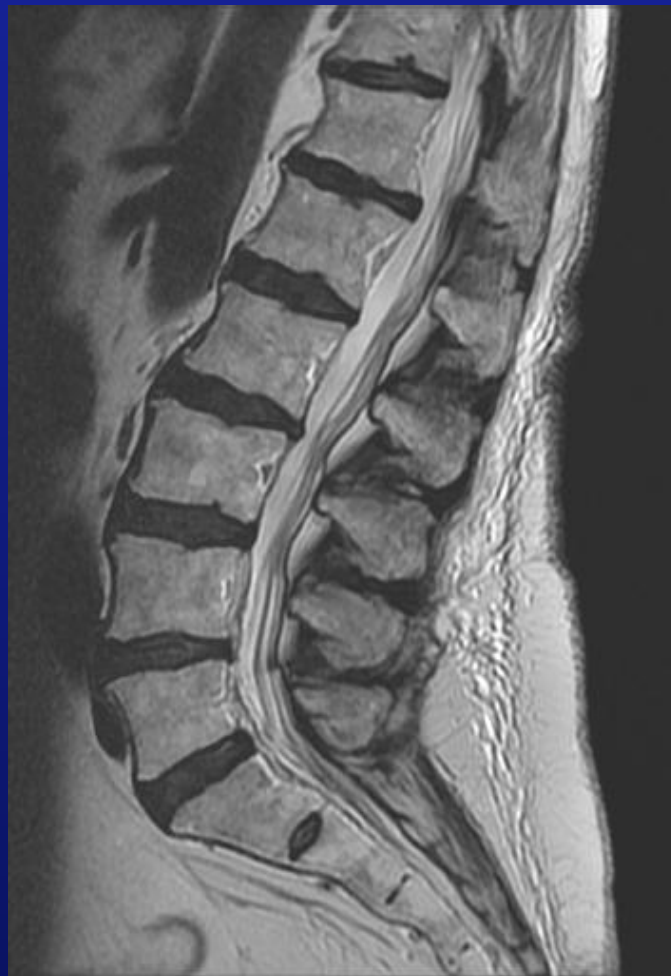

# The Lumbar MRI in Clinical Practice

Lecture Notebook



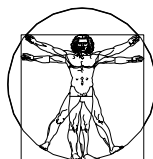
William E. Morgan, DC

# The Lumbar MRI in Clinical Practice

---

A Survey of Lumbar MRI for Musculoskeletal Clinicians

William E. Morgan



## Disclaimer and Copyright

---

The views expressed in this lecture are those of the author and do not necessarily reflect the official policy or position of the Department of the Navy, Army, Department of Defense, nor the U.S. Government.

Nothing in the presentation implies any Federal/DOD/DON endorsement.

Copyright © 2011 Text by William E. Morgan, DC

All rights reserved. No part of this book may be reproduced in any form, or by any electronic, mechanical, or other means without prior permission in writing from the publisher.

# Preface

---

While there are books written on the subject of systematic interpretation of the Lumbar MRI, they are written from a radiologist's perspective. This presentation is an attempt to help practitioners who actually treat lumbar spinal conditions to understand how the radiologist's interpretation relates to their patients. This book is not intended to be a replacement for using a radiologist, it is intended to magnify the effectiveness of the practitioner-radiologist relationship. My background is not radiology, but manual treatment of spinal conditions. I have learned long ago the value and limitations of a radiologist's report. The value is their expert interpretation; the ability to identify pathology, injury, and anatomical variance. With the advent of computer enhanced imagery, such as CT and MRI, the amount of data available to a radiologist has increased tremendously. With this increase in the available images, the radiologist must decide what information is important and which information is incidental. I have come across MRI studies that a ten page report would not be enough room to describe the specific findings. The quality of MRI has improved so much that it is difficult to find images that are totally unremarkable.

The knowledge gained in this book is not a replacement for the many years of training and experience that create board certified radiologists.

This book is intended to be used within the safety net of a qualified radiologist.

## The Physics of MR

---

**“Never worry about theory as long as the machinery does what it's supposed to do.”**

Robert A. Heinlein, *Waldo & Magic, Inc.* (1950)

The physical science behind MRI was intentionally omitted from this manual. While I do understand the importance of knowing the science behind this medium, I do not have the inclination nor the background to discuss the physics of MRI in this book. I would encourage those interested in knowing more about this aspect of MRI to delve deeper into this subject through another author. This book will concentrate on the clinician's need to extract clinical data from the images, rather than learn how an MRI works. I would compare my approach to driving a car with no intricate knowledge of how the engine works, as opposed to learning the mechanics and engineering theories of the automobile before driving. In short, you can drive the car without understanding how the engine works, and for our needs you can understand some diagnostic principles of MRI (within the safety net provided by a qualified radiologist) without knowing the detailed physics.

# Contents

---

|   |                    |
|---|--------------------|
| <a href="#">1 The Clinician's Perspective</a>                                     | <a href="#">1</a>  |
| <a href="#">2 Introduction to the Systematic Interpretation of the Lumbar MRI</a> | <a href="#">6</a>  |
| <a href="#">3 Anatomy of the Lumbar Spine on MRI</a>                              | <a href="#">13</a> |
| <a href="#">4 Standardized Anatomic Reference Descriptions</a>                    | <a href="#">24</a> |
| <a href="#">5 Classification of Lumbar Disc Lesions</a>                           | <a href="#">28</a> |
| <a href="#">6 Classification of Annular Tears</a>                                 | <a href="#">37</a> |
| <a href="#">7 Hemangiomas</a>   | <a href="#">41</a> |
| <a href="#">8 Spondylolysis and Spondylolisthesis</a>                             | <a href="#">44</a> |
| <a href="#">9 Conjoined Nerve Roots</a>   | <a href="#">57</a> |
| <a href="#">10 Classification of Spinal Cord Tumors and Masses by Location</a>    | <a href="#">62</a> |
| <a href="#">11 Perineural (Tarlovs) Cysts</a>                                     | <a href="#">73</a> |
| <a href="#">12 Stenosis</a>   | <a href="#">77</a> |
| <a href="#">13 Modic Changes on MRI: Vertebral Body Marrow Morphology</a>         | <a href="#">80</a> |
| <a href="#">14 Post-Surgical Findings</a>   | <a href="#">86</a> |
| <a href="#">15 Systematic Sequence of Interpretation</a>                          | <a href="#">94</a> |

---

# The Clinician's Perspective

---

1

## Why should a Clinician Study Lumbar MRI?

It has been said that a picture is worth a thousand words. I believe that this adage is true if you understand what you are observing. The radiology report is an attempt to describe what is seen in a radiographic image with words. This will work well for describing overt pathology, injury, or obvious clinically significant findings. A picture is worth a thousand words, yet the average radiologist report fails to have even a thousand words.

Radiologists are economical in their use of words in their reports, so by necessity the radiologist must triage what findings reach the written report. With advanced imagery technology, such as CT and MRI, so much information is available that if a radiologist were to describe everything visible in every slice of imagery, the report could conceivably be ten to twenty pages in length. A report of that length would be impractical for both the radiologist and the requesting provider. So the radiologist must try to determine what findings are clinically significant and then concisely pass these on to the requesting provider.

Prior to the innovation of MRI and CT, spinal specialists used clinical findings correlated to X-rays, and myelograms (myelograms use a special dye and an X-ray to identify spinal lesions). When MRIs became available with their increased specificity and sensitivity, a high percentage of the studies yielded the identification of disc herniation. This resulted in an increase in the number of lumbar disc surgeries until it was determined that in many people a disc herniation and other spinal lesions are considered a coincidental finding. Just because you find a derangement or anomaly, does not mean that it is clinically significant. Combining the patient history and physical examination to an MRI will help in determining the clinical relevance of a finding on MRI.


We can expect the radiologist to identify most pathology, diagnostic findings such as disc derangements, and findings with a potential of being clinically significant. What they do lack is first hand knowledge of the patient.

Below is the description of a famous work of art. It is written from a detached point of view that is uninformed about the people and events in the painting. It is accurate in every way, but lacks sufficient background knowledge to clearly state what is happening.

### **Image Report**

This painting appears to be an oil on plaster painting. This image demonstrates a well-developed white male reclining on a green slope leaning on his right elbow. He is nude and devoid of body hair. This man is located on the left side of the painting and is looking at another older man on the right side of the painting. The man on the left is casually reaching his left hand toward the older man. The older man has long gray hair and a beard, but is well muscled. The older man is surrounded by eleven nude young children and is shrouded in a red cloth. He is wearing a shear short sleeved tunic. The older man is reaching his right arm with an extended index finger toward the hand of the younger man.

Here is the painting that was described on the previous page. With a historic perspective you may clearly see that image is the romanticized duplication of God reaching out to Adam during creation painted on the ceiling of the Sistine Chapel by Michelangelo di Lodovico Buonarroti Simoni . While the description of this painting on the previous page was accurate in everyway, it lacked the historic and visual perspective that provides the viewer with the immediate knowledge of the significance of the painting.

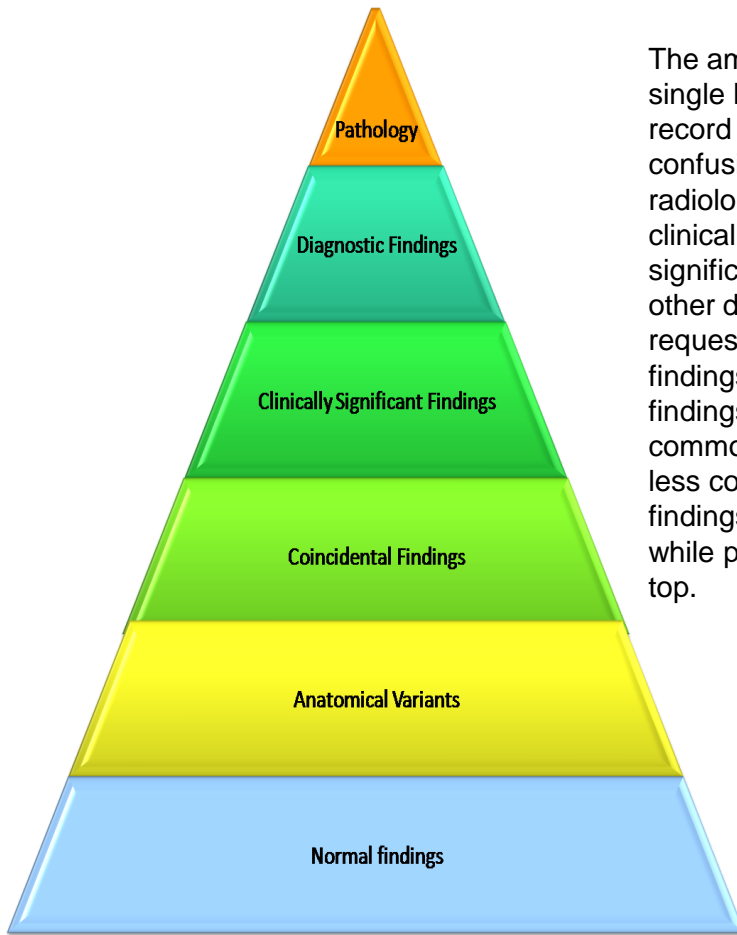


The Creation of Adam by Michelangelo di Lodovico Buonarroti Simoni 1512, Sistine Chapel

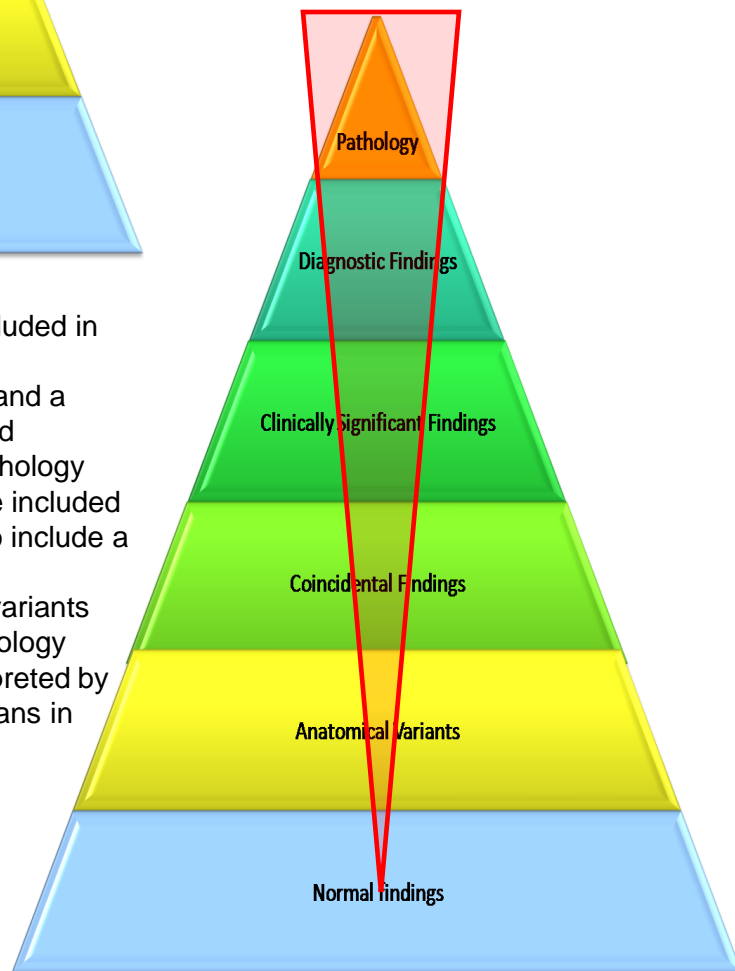
It is my contention that the historical perspective is important in obtaining information of clinical significance. From my perspective of watching neurosurgical morning reports, it is quite obvious that while they defer to the opinion of the neuroradiologist, the neurosurgeons connect their history and physical exam with their own interpretation of MRIs to obtain a specific diagnosis. The MRI is a tool that should be in the hands of everyone who treats the spine, and a clinician-radiologist collaborative team is preferred to having two distinct and non-conversing professions. That collaboration begins with the clinician providing the radiologist with adequate historic and clinical perspective to help the radiologist understand why the study was requested and progresses to the radiologist correlating the radiographic findings to the clinical profile of the patient. For most cases this level of communication is sufficient, but there will be times where only direct interaction between the clinician and the radiologist will suffice. The radiologist may need more clinical information or recommend another study or protocol to better visualize what the clinician wants to see. The clinician may ask the radiologist to expound on the findings or to elaborate on an nuance found in the image. The clinician-radiologist relationship should be a healthy relationship built on clear communication.



# What makes it into a radiology report?



The amount of information to a radiologist on a single MRI study is vast. So vast that to attempt to record all findings is not practical and would add confusion to the average practitioner. What is on radiology reports is most pathology and most clinically significant findings, as deemed significant by the radiologist, and a smattering of other details that may be pertinent to the requesting provider. This pyramid represents the findings that are visible on MRIs. It shows that the findings with less of a clinical impact are more common, and the more significant findings are less common, but more significant: Normal findings and anatomical variants are on the bottom while pathology and diagnostic findings are at the top.



The red inverted triangle represents what is included in radiology reports. Since a report that included everything could consume an hour of dictation and a ream of paper, the radiologist must prioritize and economize what is reported. Of course all pathology and diagnostically significant findings should be included and most are included. The radiologist will also include a smattering of other findings that have potential significance: coincidental findings, anatomical variants and the like. This book will not replace the radiology report, and certainly every MRI should be interpreted by a board certified radiologist, but it will aid clinicians in expanding their use of the lumbar MRI past the limitations of a written MRI report.

## MRI findings in Asymptomatic Patients

There have been several studies over the years that have found significant MRI findings in asymptomatic subjects. Many of these findings on MR had previously been considered to cause pain and infirmity. Jensen and associates<sup>1</sup> performed scans on 98 asymptomatic individuals. Of the 98 individuals without symptoms, only 36% had normal lumbar discs at every level, 27% had disc protrusions, 1% had an extrusion, 52% had disc bulges at one or more levels, and annular tears were present in 14%.

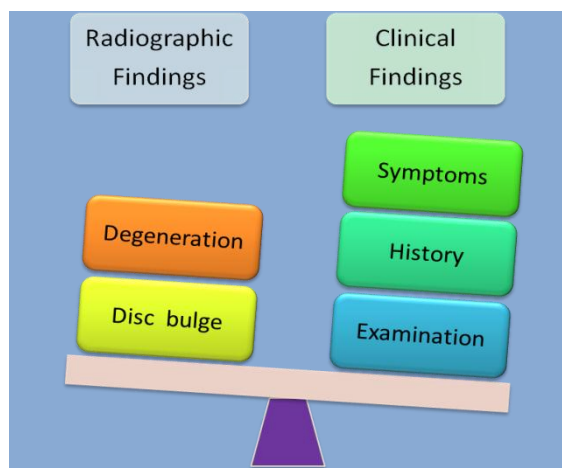
In another study performed by Boden<sup>2</sup> et al., 67 people who never had lower back pain received lumbar MRIs. In those individuals younger than 60 years old, 20% had a disc herniation, while those older than 60 had a herniation rate of 36% and 21% had spinal stenosis.

Weishaupt<sup>3</sup> studied 60 asymptomatic people between the ages of 20 and 50. In this population 62-67% had lumbar disc bulges or herniations, 32-33% had annular tears, and 18 % had disc extrusions.

These (and other) studies clearly demonstrate the need to correlate a patient's clinical presentation with the findings on lumbar MRI. Coincidental or incidental findings can lead the practitioner on a grand wild goose chase while creating anxiety in the patient. We need to be careful in discerning between findings that have clinical implications and those findings which are merely incidental.

## Balancing the Weight of Clinical and Radiographic Findings

With the incredibly large amount of detail that is visible on an MRI, it would be easy to get bogged down in the coincidental findings of an MRI. Just because there is a finding visible on MRI does not mean that it is clinically significant. Herniated discs are often seen on MRIs of patients with no clinical manifestation of the condition. The flip side of learning to read MRI is that the sensitivity of this technology is so great that there can be too much information. All radiographic findings must be correlated to history and clinical findings. So I offer a word of warning to the non-radiologists: Do not jump to conclusions; most MRI findings should be collaborated with the patient's complaints and findings on clinical examination. The exception is the finding of pathologies which may lay dormant clinically, but still require intervention.



1) Jensen et al. (1994). Magnetic resonance imaging of the lumbar spine in people without back pain. *New England Journal of Medicine*, Jul 14;331(2):69-73

2) Boden et al. (1990). Abnormal magnetic-resonance scans of the lumbar spine in asymptomatic subjects. A prospective investigation. *J Bone Joint Surg Am*. 1990 Mar;72(3):403-8.

3) Weishaupt et al. (1998). MR imaging of the lumbar spine: prevalence of intervertebral disk extrusion and sequestration, nerve root compression, end plate abnormalities, and osteoarthritis of the facet joints in asymptomatic volunteers. *Radiology*. 1998 Dec;209(3):661-6.

# Introduction to the Systematic Interpretation of the Lumbar MRI

---

2

# Orientation and Sequencing of the Lumbar MRI

Without a systematic approach, endeavoring to interpret MRIs would be a daunting task. Efficient interpretation of the lumbar MRI entails several components: identification of the image orientation, the MRI image type (T2W, T1W, fat suppressed T2W, etc.), the knowledge of the anatomical structures (normal and variants of normal), and the ability to identify injury, abnormality, and pathology. This chapter will introduce a simple system for analyzing lumbar MRI studies.

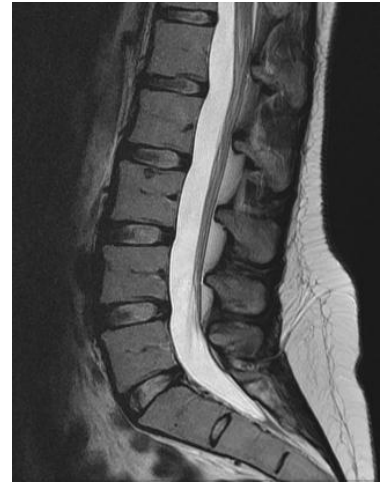## Image Orientation

There are three planes of orientation that are common in MRI studies: Sagittal, axial, and coronal.

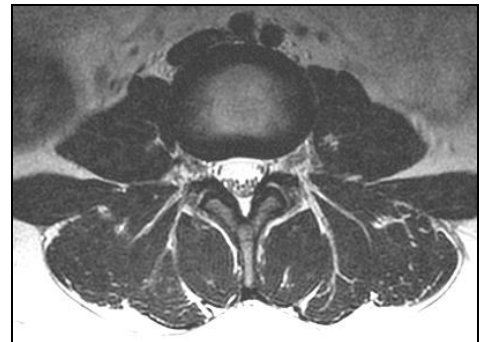
**1. Sagittal Images-** Sagittal images are oriented in a lengthwise view allowing the visualization of the entire lumbar spine in one image. In some aspects the sagittal image resembles a lateral lumbar X-ray. The difference is that the sagittal image shows a slice through the body at a particular anterior to posterior slice. After identifying the sagittal image, determine the left-right orientation

**2. Axial Images-** Axial images reveal cross-sectional anatomy of the spine and paraspinal structures. In the axial image the structures appear reversed. The structures from the left side of the body will appear on the right side of the axial image. This is easier to remember and conceptualize if you envision the patient's feet being toward the viewer.

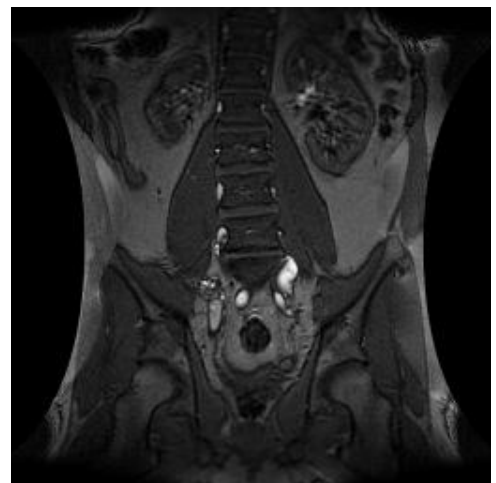
**3. Coronal Images-** Coronal images are full length studies that show the left to right width of the structures studied. These images are usually only included in the spotting/orientation views and are not commonly included in the detailed bulk of the lumbar MRI studies.



Sagittal View

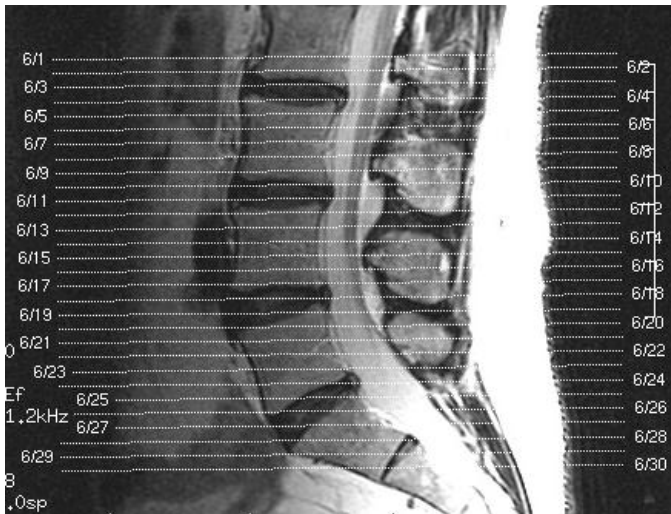

Axial View

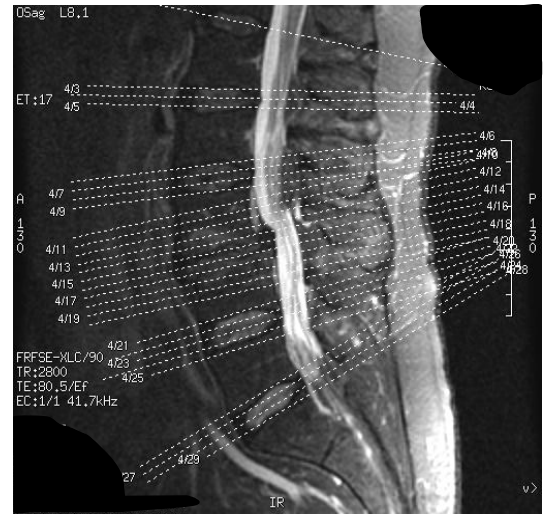

Coronal View





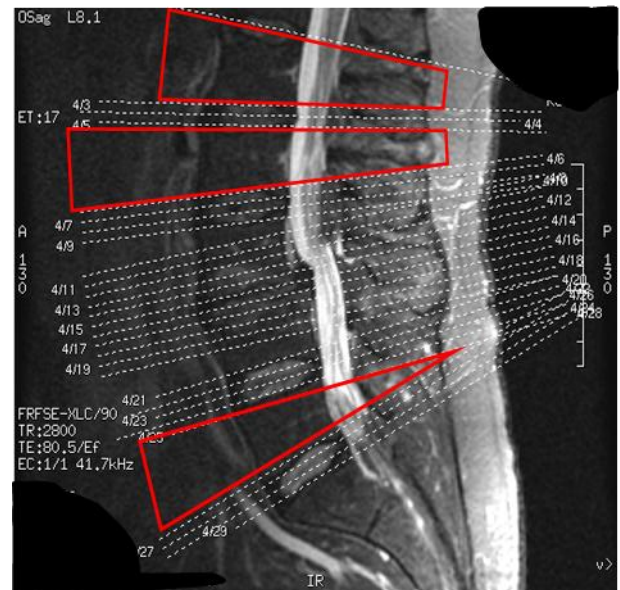
**Image 1.** Uniform horizontal slices



**Image 2.** Slices along the disc planes.

In most lumbar MRIs the axial slices will be evenly spaced intervals (image 1). Some studies will emphasize only special regions of anatomy or a site of concern such as the site of an injury, degeneration, or disease, or a study may be limited to the disc spaces (image 2). They may even be angled to correlate to the angles of the vertebrae and disc spaces. These spotting or scout films indicate that the technician selected slices through the disc spaces and through an area of particular concern. The technician also made sure that the slice angles aligned with the anatomic variations of the lumbar segments. Note that there are areas of the lumbar vertebra which are not visualized at all.

The red lines in the scout film of image 3 reveal large areas of the lumbar spine that are not represented in axial imagery. This study was particularly intended to visualize a condition affecting the L3-4 vertebrae and disc along with the intervertebral disc spaces of the rest of the lumbar spine.



**Image 3.** Selective slices of anatomy of particular interest. Note the red bordered sections with no slices.

## MRI Image Type

MRI image types enhance various tissue types differently. This allows the differentiation of tissues by the specialist. The various types of MRI images are as follows:

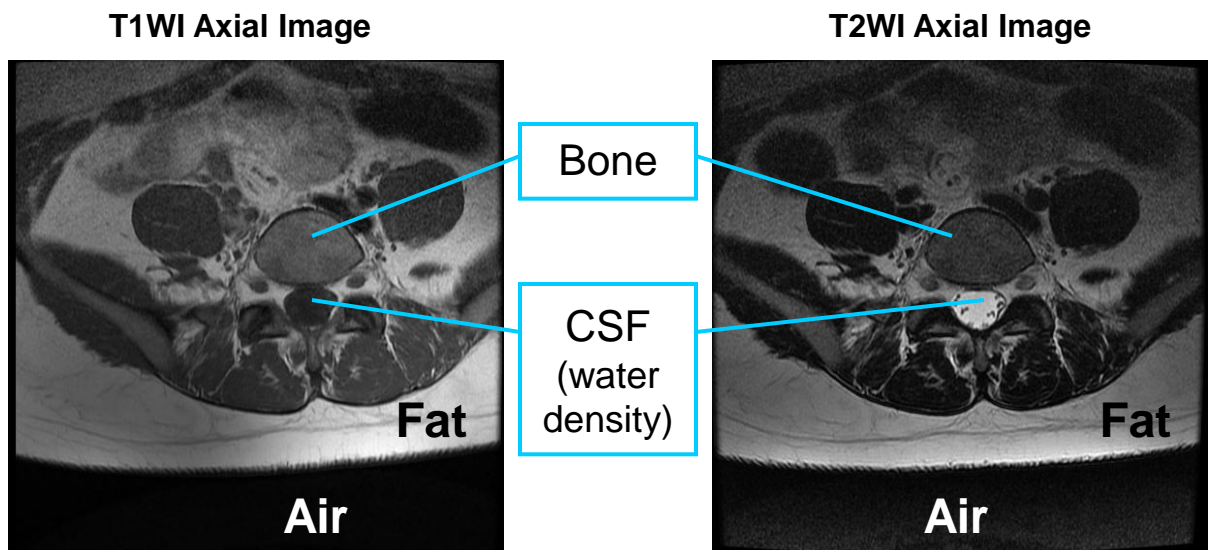
- 1. T1 Weighted Image** Water densities are dark, fat densities are bright. T1WI have greater anatomic detail than T2WI.
- 2. T2 Weighted Image** Water and fat densities are bright, muscle appears intermediate in intensity.
- 3. Fat Suppressed T2 Weighted Image** Water densities are bright, fat is suppressed and dark
- 4. Intermediate T2 Weighted Image** Ligaments and cartilage are viewed as very dark
- 5. Gadolinium Enhanced T1 Weighted Image** Gadolinium is an injected enhancement. It is used to identify pathology.
- 6. Fast Spin Echo (FSE)** Frequently used in musculoskeletal imaging. Allows quicker image acquisition. Fat is bright on T2 weighted images. Marrow or subcutaneous pathology may not show unless fat suppression is used.
- 7. FSE STIR (Short T1 Inversion Recovery)** – Decreased signal intensity (brightness) from fat and an increased signal from fluid and edema. This is useful in identifying soft tissue and marrow pathologies.
- 8. Proton Density** -Proton density uses a mixture of T1 and T2 images. It is characterized by enhanced anatomical detail and poor tissue contrast.
- 9. Fat Saturation-** Fat saturation employs a “spoiler” pulse that neutralizes the fat signal without affecting the water and gadolinium signal. Fat Saturation is used with T1 weighted images to distinguish a hemorrhage from a lipoma. When used with FSE T2 weighted images, fat saturation can enhance marrow or soft tissue pathology.
- 10. FIESTA (Fast Imaging Employing Steady sTate Acquisition)**-This method of image acquisition captures structures rapidly and provides high quality images of fluid filled structures.

## Comparing T1 to T2 Weighted Images

### MRI Image Characteristics

For practical purposes the most commonly utilized types of MRI images by non-radiologists are T1 and T2 weighted images. T1 has greater anatomic detail, but T2 tends to be the favored image type for observing the intervertebral disc and the spinal cord. The chart below reflects the characteristics of each image type. These images highlight the characteristics of T1 & T2 images.

| Tissue | T1      | T2      |
|--------|---------|---------|
| Bone   | Neutral | Neutral |
| Air    | Dark    | Dark    |
| Fat    | Bright  | Light   |
| Water  | Dark    | Bright  |



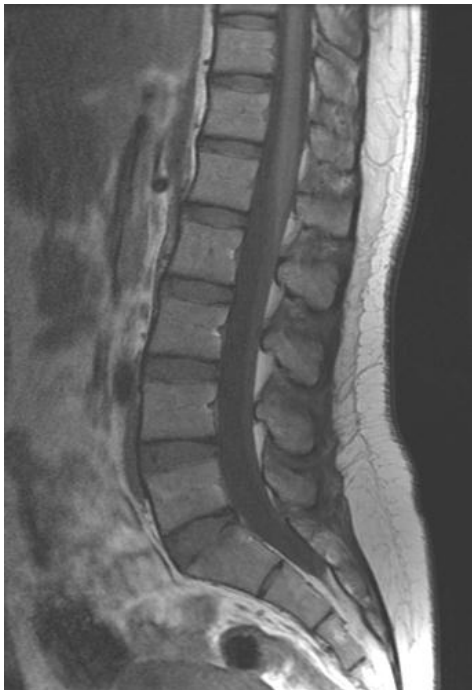Note that some tissues are dark (low intensity signal) on both image types. These include: gas, cortical bone, calcification, tendons/ligaments, and menisci.



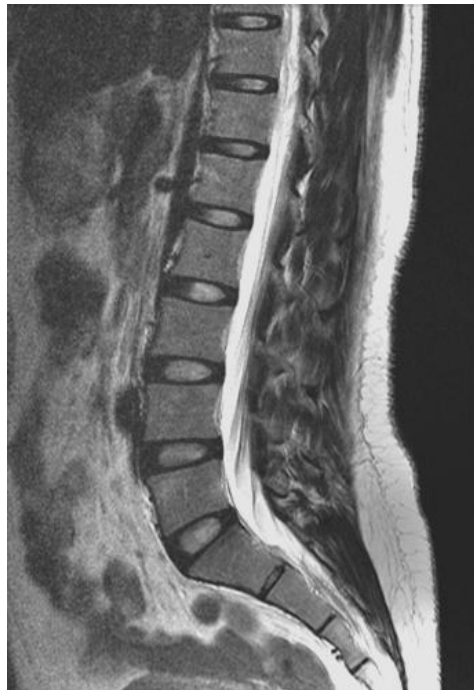## How are T1 and T2 weighted images alike?

For comparison purposes the two sagittal images, have been placed side by side with T1 on the left and T2 on the right,. Note that on both images the vertebral bodies are a neutral gray color, muscles and ligaments are dark, that air is black, and that fat is light colored.

**T1 Weighted Sagittal Image**



**T2 Weighted Sagittal Image**



## How do T1 and T2 weighted differ?

The difference is black and white. In T1 images water is black while T2 images display water as white. The blackness of water in T1 images makes it more difficult to differentiate the cerebral spinal fluid from the nerves, and the disc from the contents of the central canal. However, the T1 image aids in the discerning details of other anatomic structures.

# Anatomy of the Lumbar Spine on MRI

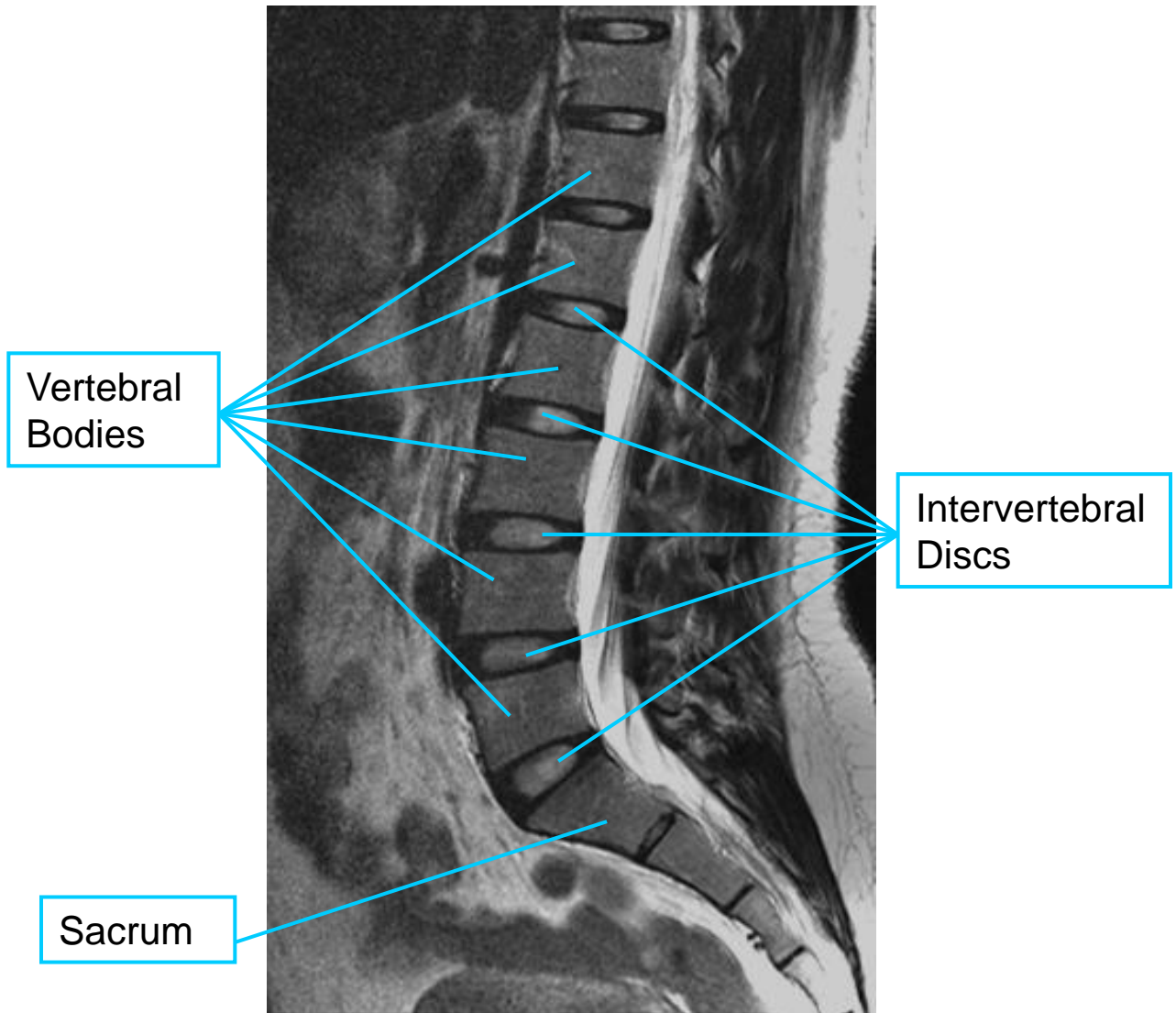
---

3

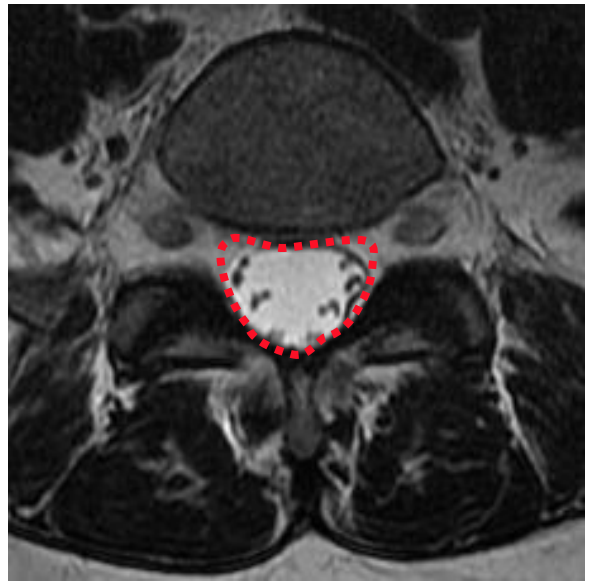
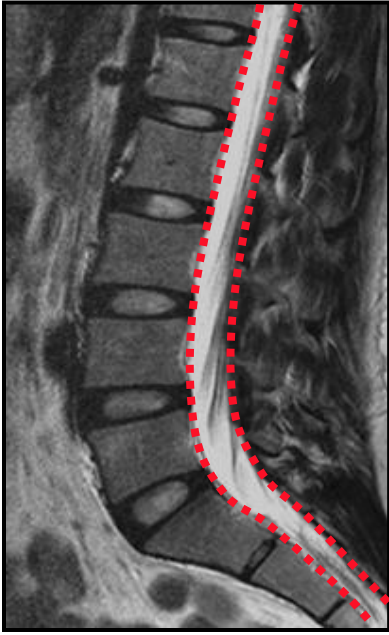
## Anatomy

In addition to knowing the image orientation and MRI image type, it is important to have a good foundation in the anatomy of the lumbar spine as viewed on MRI. This chapter will review the lumbar anatomy as viewed in various sequences.

This sagittal T2 weighted image demonstrates typical vertebrae, sacrum, and intervertebral discs. The light colored disc in a T2 weighted image is indicative of a healthy well-hydrated disc. The light colored zones in the nucleus pulposus appear brighter than the annular fibers. The vertebrae remain neutral gray in color. A normal lumbar lordosis is visualized.

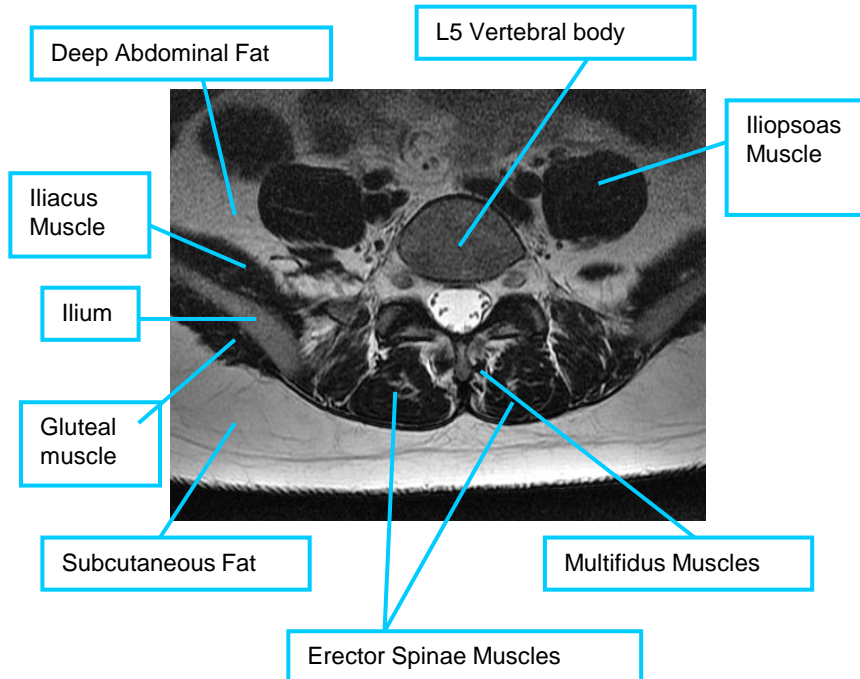


## The Central Canal



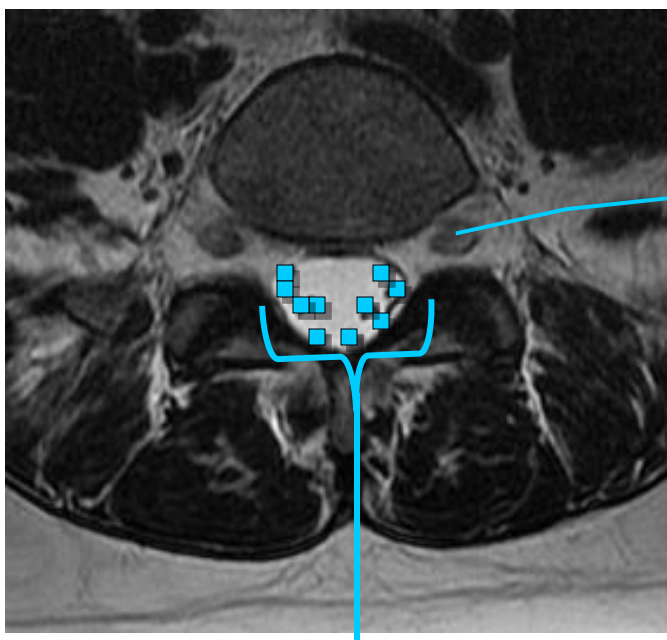
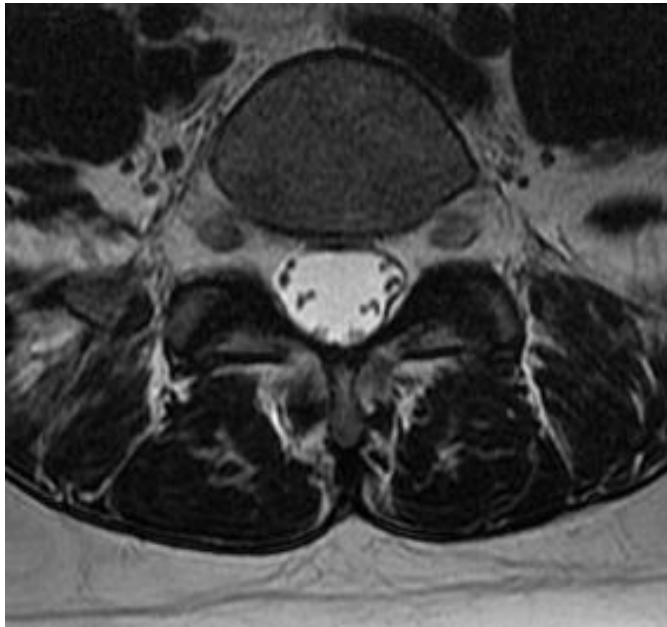
The central canal is outlined with a red dotted line in these sagittal and axial T2 weighted images.

## Anatomy of an Axial Slice Through L5



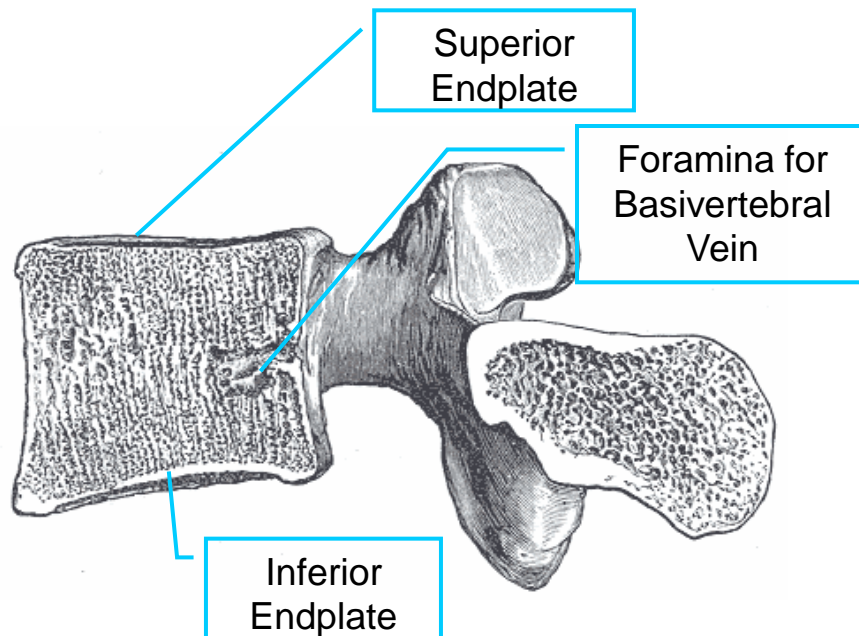
This image, a T2W sagittal slice through the level of L5, reveals the cross-sectional anatomy of this plane. Recall that in T2 images water density is bright, fat is light colored (but not as bright as water), air is black, muscles are dark, and bone is a neutral gray.

The exiting nerve root expands into the dorsal root ganglion as it exits the intervertebral foramina. The nerve roots are surrounded by fat from the point that they exit the thecal sac and transverse the foramina. Within the thecal sac, nerve rootlets (identified by blue in the lower figure) are surrounded by cerebral spinal fluid (CSF) which is bright in color.

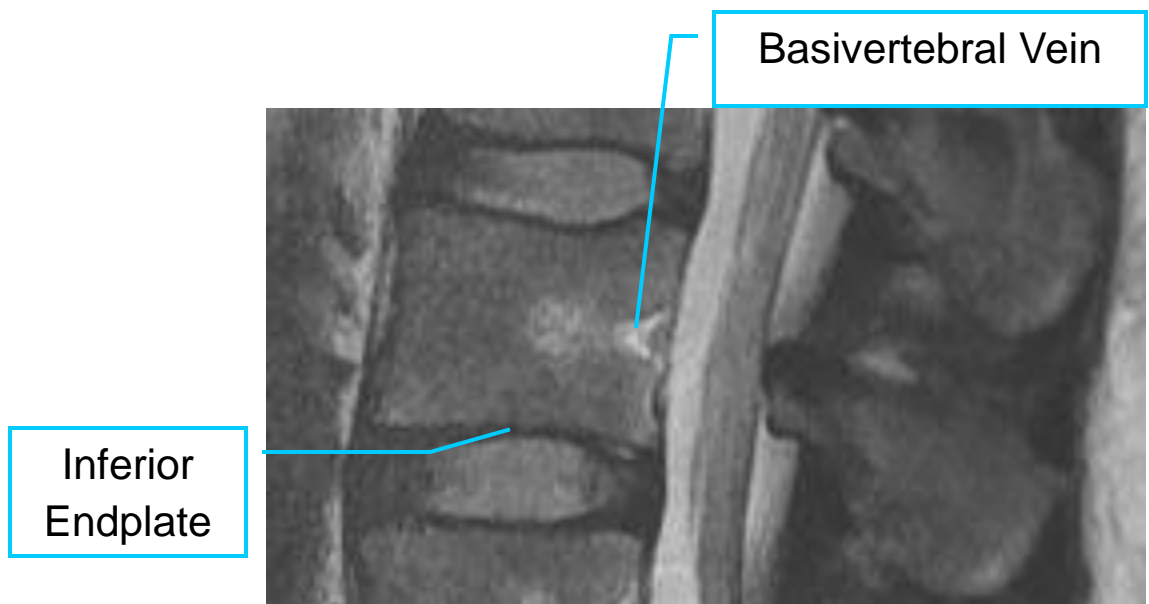


Exiting nerve root (the dorsal root ganglion)

Nerve rootlets of the cauda equina

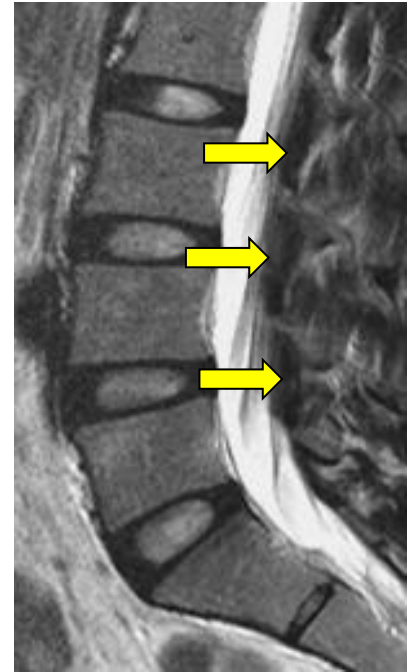
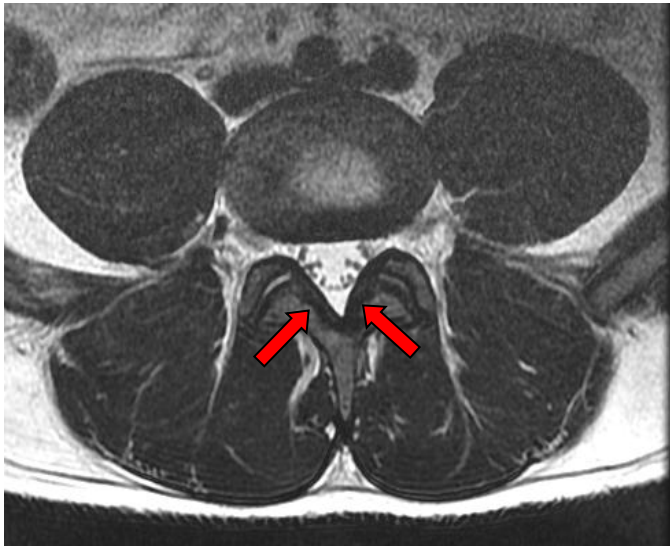


Images adapted from Henry Gray (1821–1865). *Anatomy of the Human Body*. 1918.

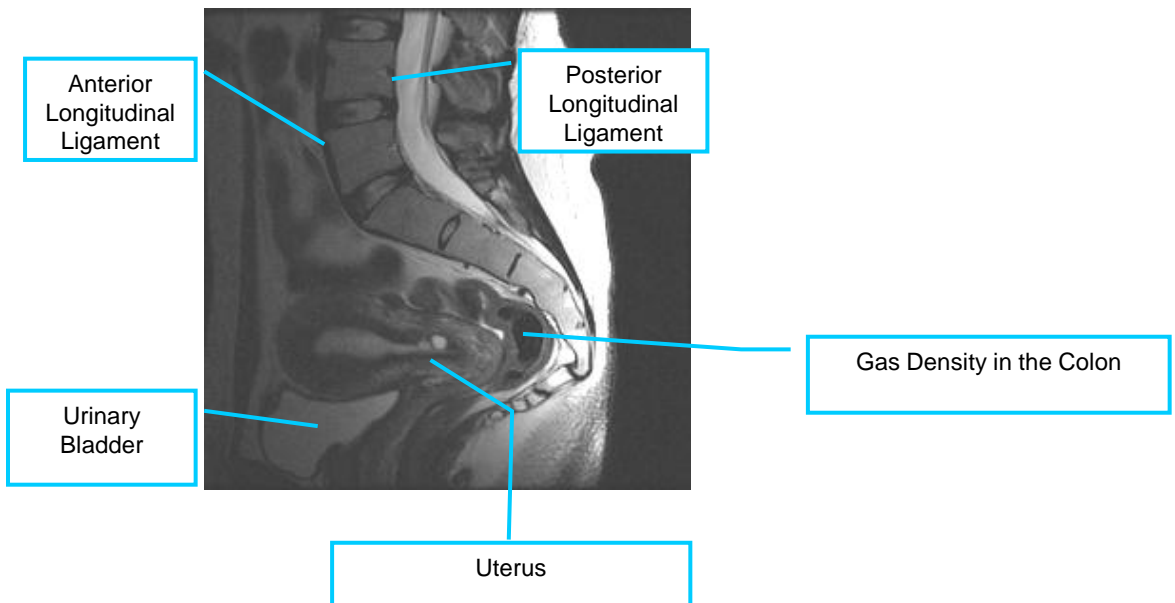


## Ligamentum Flavum

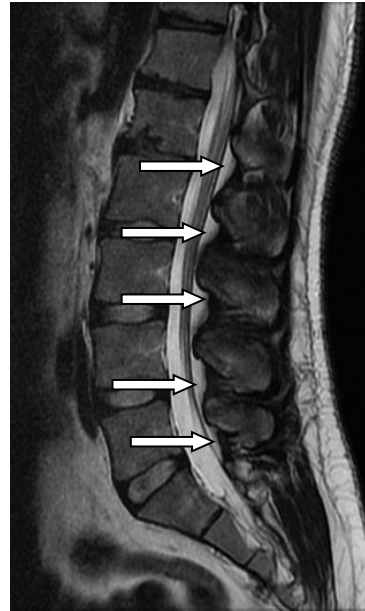
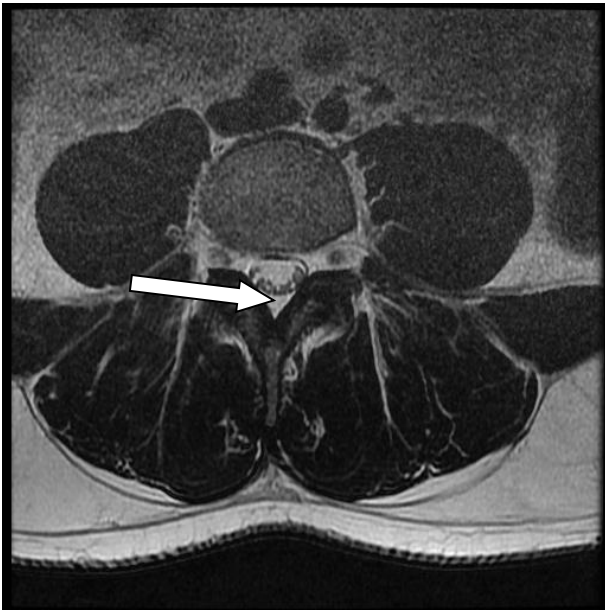
There are several ligaments that stabilize and support the spine. Of those the ligamentum flavum is of particular interest to the clinician. It comprises the posterior boundary of the spinal canal and normally appears as a “V” on axial slices (red arrows). On sagittal images the ligamentum flavum is seen at the posterior of the spinal canal (yellow arrows).



## Sagittal Lumbopelvis

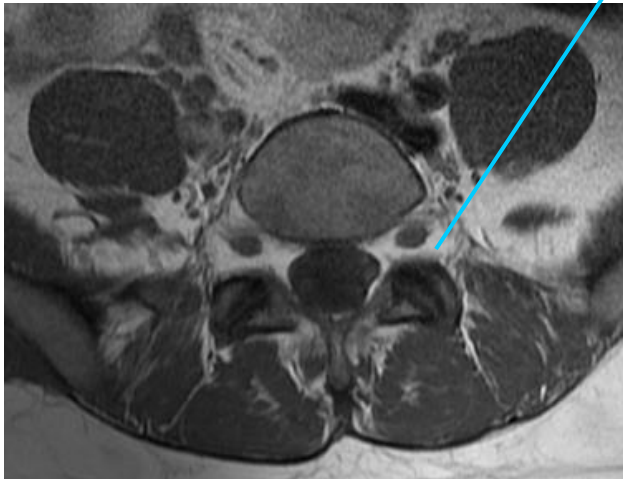


## Normal Spinal Fat Distribution

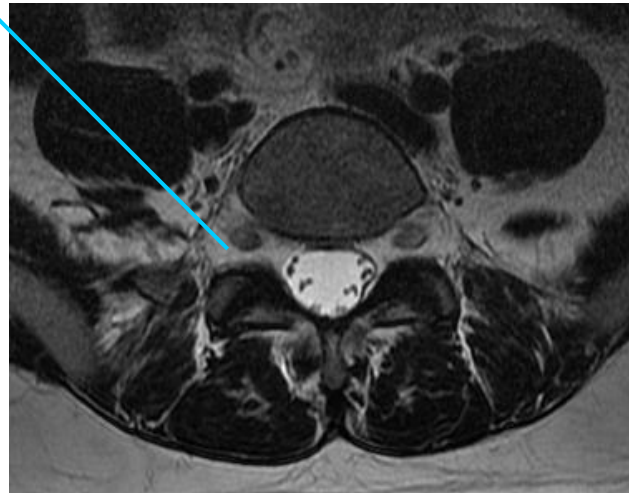


Normal fat distribution within the spine: epidural fat is located in the posterior recess of the spinal canal. The white arrows identify normal epidural fat which appears light in these T2WI.

The exiting nerve roots are surrounded by fat (fat is light on both T1 and T2 weighted image) as it traverses the IVF.



T1 weighted axial image



T2 weighted axial image

The nerves are surrounded by fat as they traverse the IVF. Note the water density of the CSF is bright on the T2 and dark in the T1 images. Absence or displacement of the fatty tissue may be clinically significant.



# Anatomy from a Coronal Orientation-1

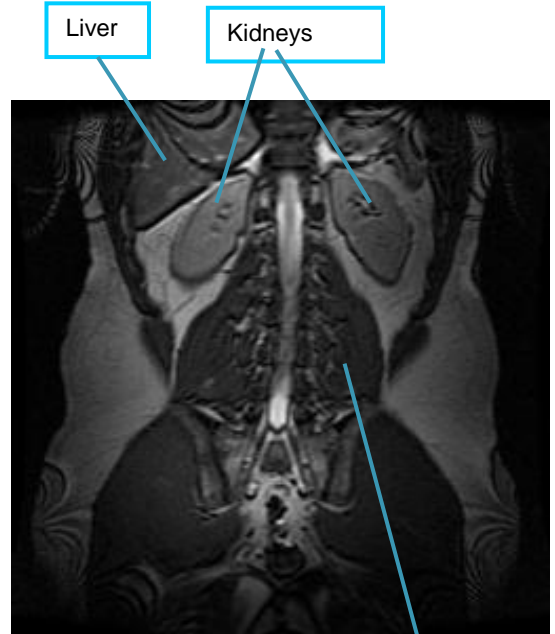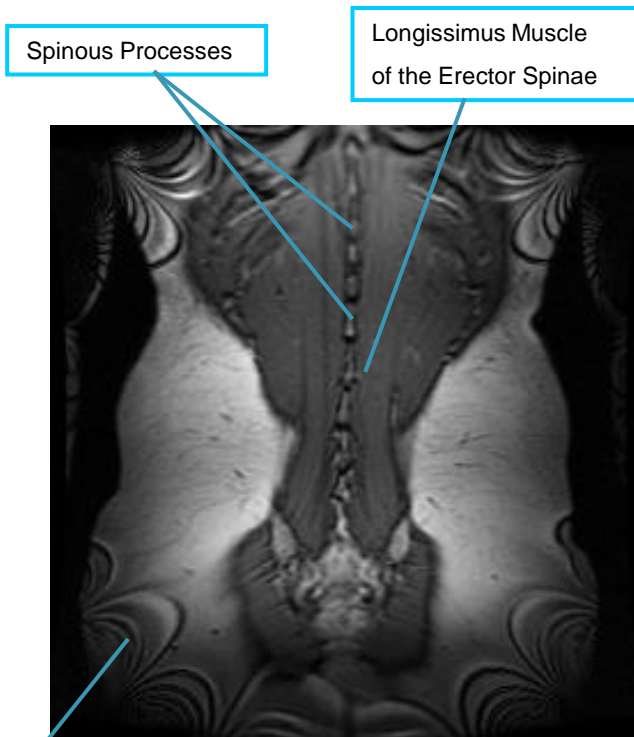
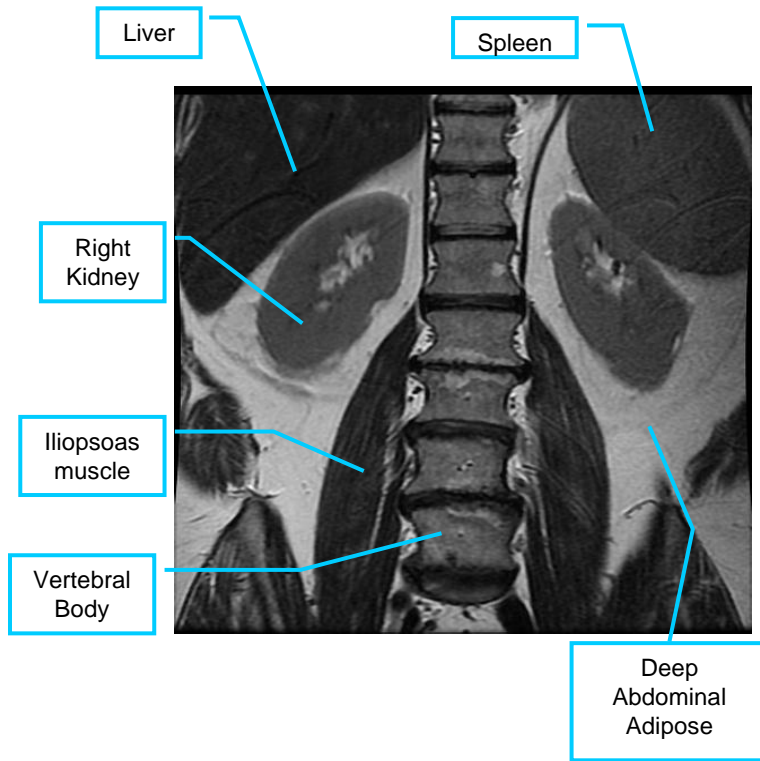
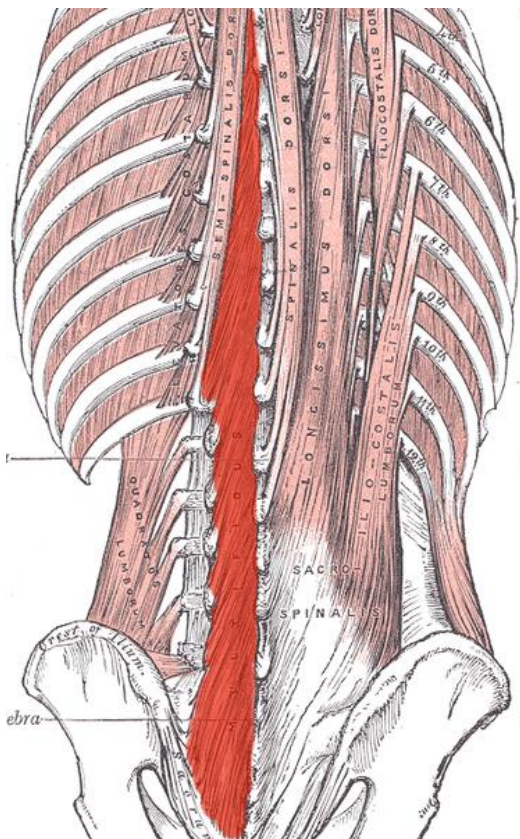


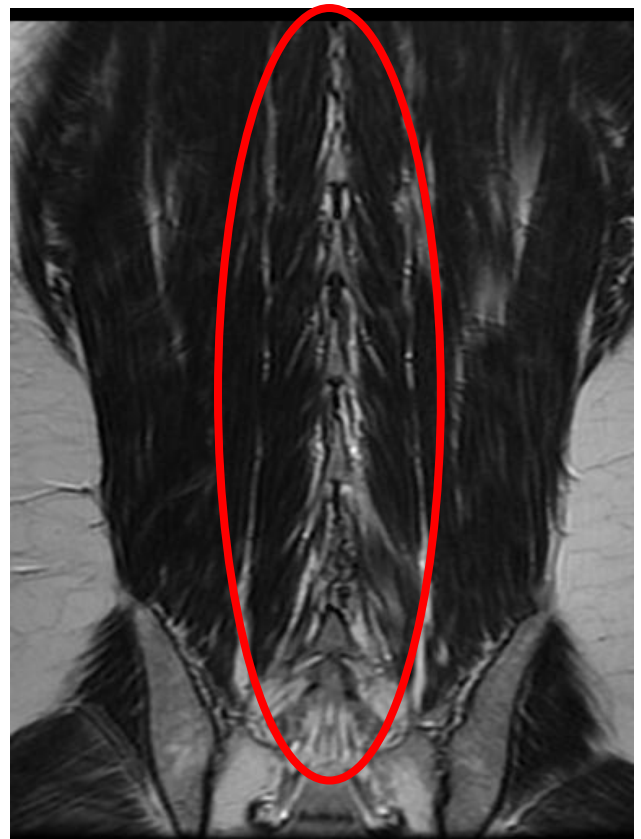
Image Artifacts

## Multifidus Muscles

The clinical significance of the multifidus muscles has become increasingly evident in recent years, and clinicians are looking for better ways to observe this interesting muscle. While coronal images are rarely used in most lumbar MRIs, they are useful in identifying the multifidus muscles. Note that the multifidus fibers do not run longitudinally like the erector spinae muscles (spinalis, longissimus, and iliocostalis), but rather obliquely from the lateral side of the spinous processes to the mamillary processes of the lumbar spine and the sacrum. In the lower lumbar and sacral region, the multifidi originate along the spinous processes and insert into the aponeurosis of the sacrospinalis muscle, the posterior superior iliac spine, and the posterior sacroiliac ligaments.



**Image 1.**

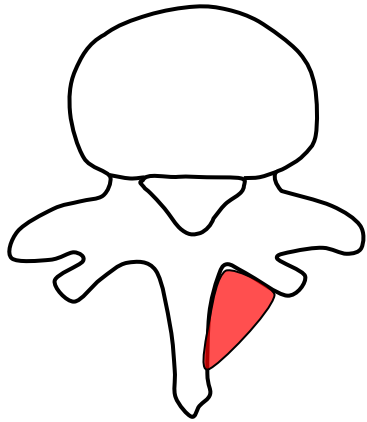


**Image 2.**

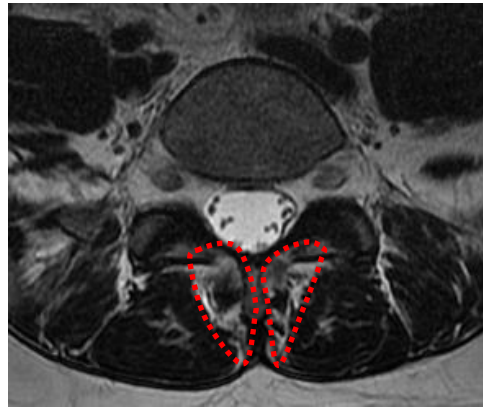
The illustration on the left (image 1) highlights the left multifidus muscles in red. The coronal MR on the right, image 2, reveals a clear view of the multifidus muscles. Note the oblique orientation of the multifidus muscles, and compare them to the longitudinal orientation of the erector spinae muscles.

Image 1 adapted from Henry Gray (1821–1865). Anatomy of the Human Body. 1918.

## Multifidus Muscle Characteristics



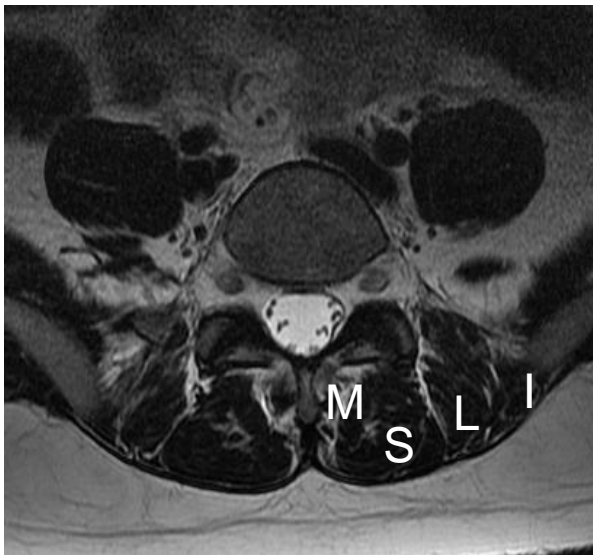
**Image 1.** Schematic of multifidus location



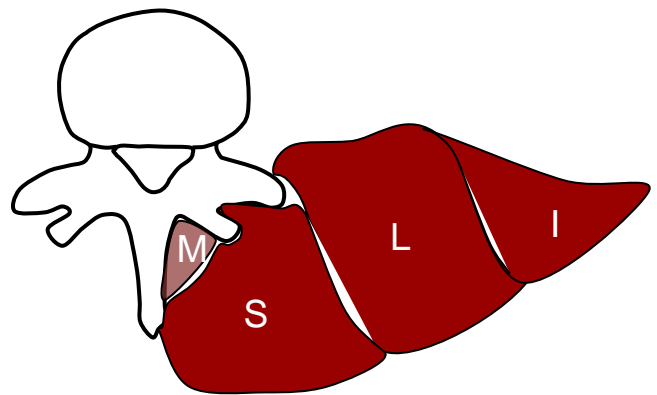
**Image 2.** T2 weighted axial denoting the location of the multifidus

In axial imagery the multifidus lies in the laminar groove bordered by a fascial/adipose boundary. The multifidus is typically a small flat muscle and subject to atrophy and fatty infiltration. The illustration on the left (image 1) demonstrates the location of the multifidus in red. The axial image on the right (image 2) the location of the multifidus is demonstrated in a T2WI within the red dotted lines.

## The Positional Relationship Between the Erector Spinae and the Multifidus



**Image 3.** T2 weighted axial image with labeled muscles



**Image 4.** Illustration of paraspinal muscles

The posterior muscles of the spine can be seen on axial imagery and are separated by fascial investment seen as the same intensity as adipose (image 3).

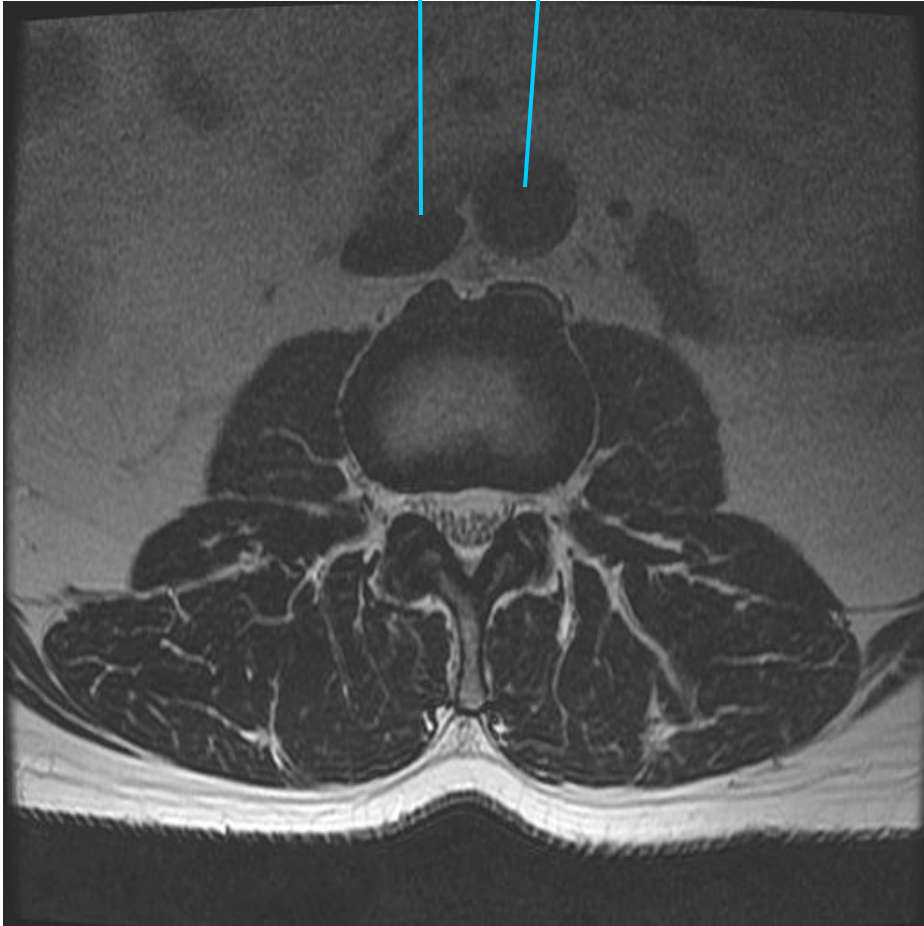The schematic (image 4) identifies the location of these muscles:

M- multifidus, S-spinalis, L-Longissimus, I-iliocostalis

## The Great Vessels

Inferior Vena Cava

Abdominal Aorta



The abdominal aorta is located on the left side of the body, [the right side of an MRI], and the inferior vena cava is on the right. The higher pressure of the aorta helps to create a more circular inflated appearance, while the inferior vena cava has lower hydrostatic pressure and appears less inflated.

# Standardized Anatomic Reference Descriptors

4

*“There is no more difficult art to acquire than the art of observation, and for some men it is quite as difficult to record an observation in brief and plain language.”*

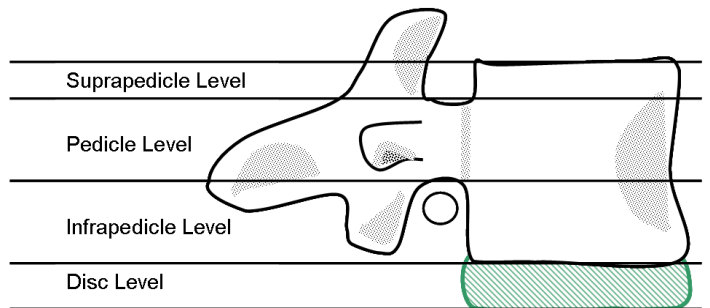
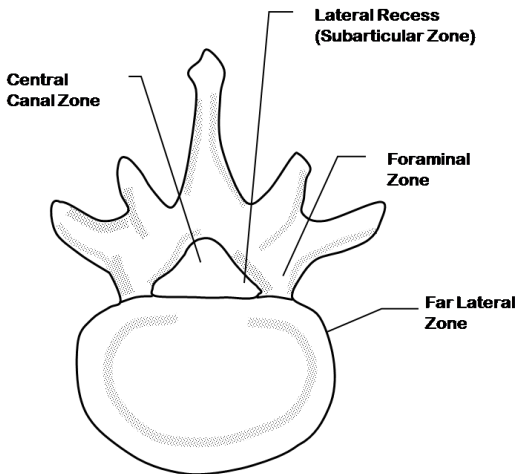
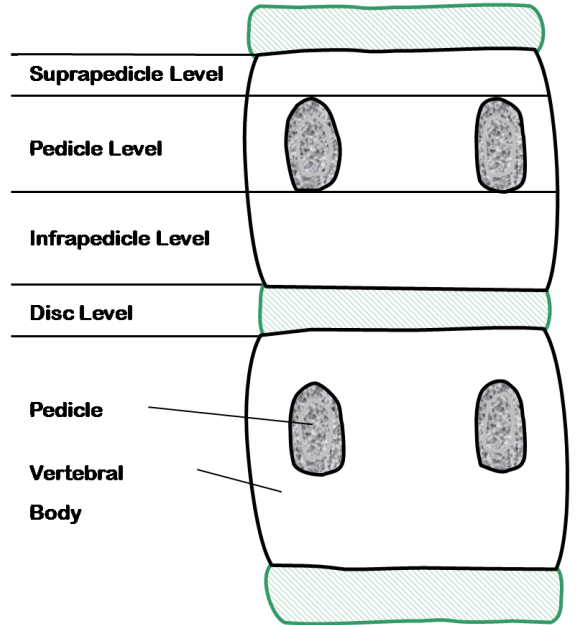
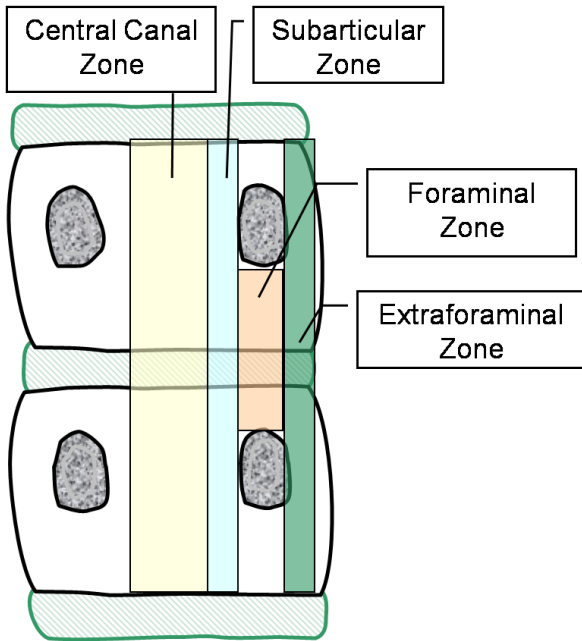
William Osler, Physician, 1849-1919

Every specialty has its own lexicon that has special meaning within their profession. This is fine when working within a given profession, but may confound those from another profession. The language of healthcare is always evolving and periodically contradictory and confusing. The condition known as Tarlovs cysts, is slowly ceding to the more descriptive term *perineural cyst*. The term HNP (herniated nucleus pulposa) is now passé, replaced by the term herniated disc (HD). Definitions evolve and change, but dissemination of the changes lags . Periodically the various specialties join forces to identify words, diagnoses, and descriptors with multiple or conflicting definitions, and through a consensus process agree on a standardized definition. The combined task forces of the North American Spine Society, the American Society of Spine Radiology, and the American Society of Neuroradiology created a guideline for standardizing the vocabulary between the various spine specialists. They published these guidelines in the March 1, 2001 edition of Spine[1]. I recommend that every spine practitioner read and apply this article. While this work proposes a guideline to standardize terms within the spine specialties, it will eventually become obsolete and will need updating. Most of the next three chapters rely heavily on this document.

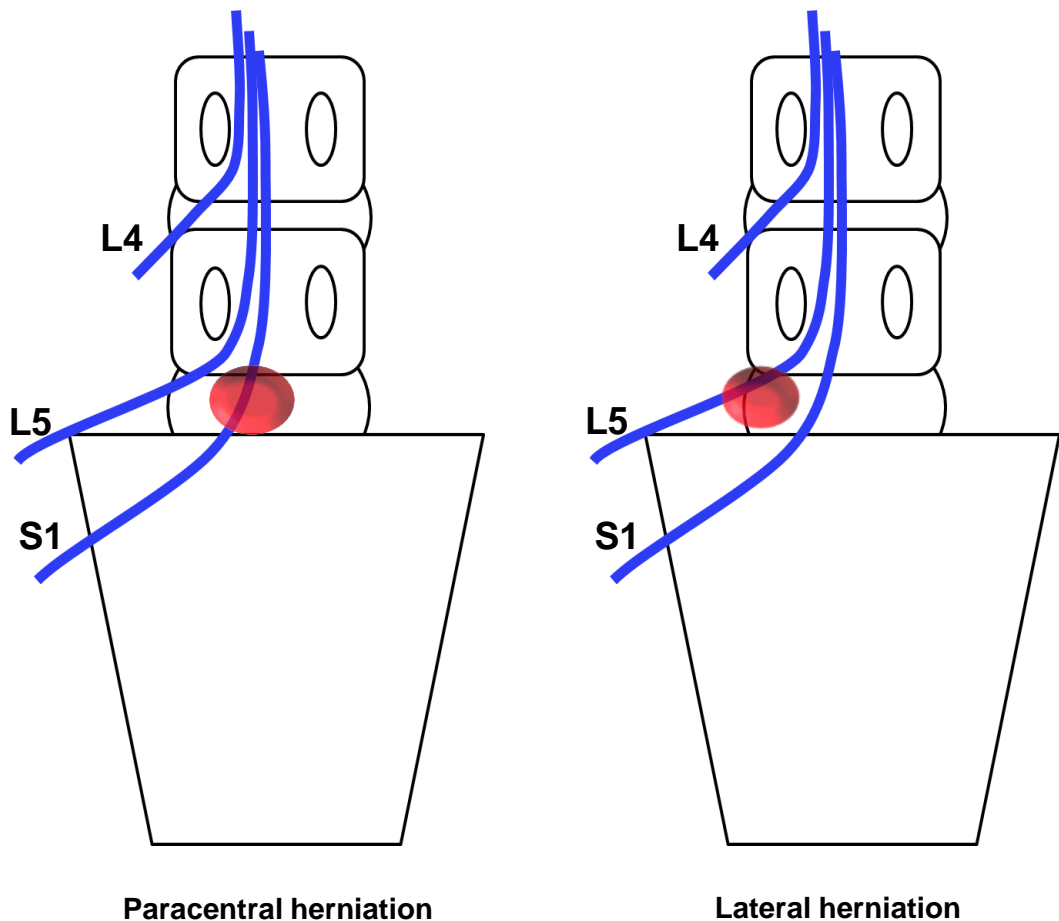
[1] Fardon DF, Milette PC. Nomenclature and classification of lumbar disc pathology: recommendations of the combined task forces of the north American spine society, american society of spine radiology, and American society of neuroradiology. Spine, Volume 26(5).March 1, 2001.E93-E113

<http://www.rsna.org/radlex/committee/ASSRDiscNomenclature.pdf>

# Location Descriptors



## Identifying Affected Nerve Roots



These schematics show the relationship of the lumbar nerves as they descend and exit the lumbar spine and sacrum. Note that the exiting nerve roots are high and lateral as they exit from the spinal canal. The descending nerve roots are more central. When there is a paracentral herniation (image on the left) it typically affects the descending nerve root, not the exiting nerve root. To affect the exiting nerve root, the herniation would usually need to have a foraminal component (image on the right).

When there is a paracentral herniation, the nerve contacted usually has the same name as the vertebra below the herniation. A paracentral herniation of the L5-S1 disc usually affects the S1 nerve root. See the illustration on the left.



# Classification of Lumbar Disc Derangements

---

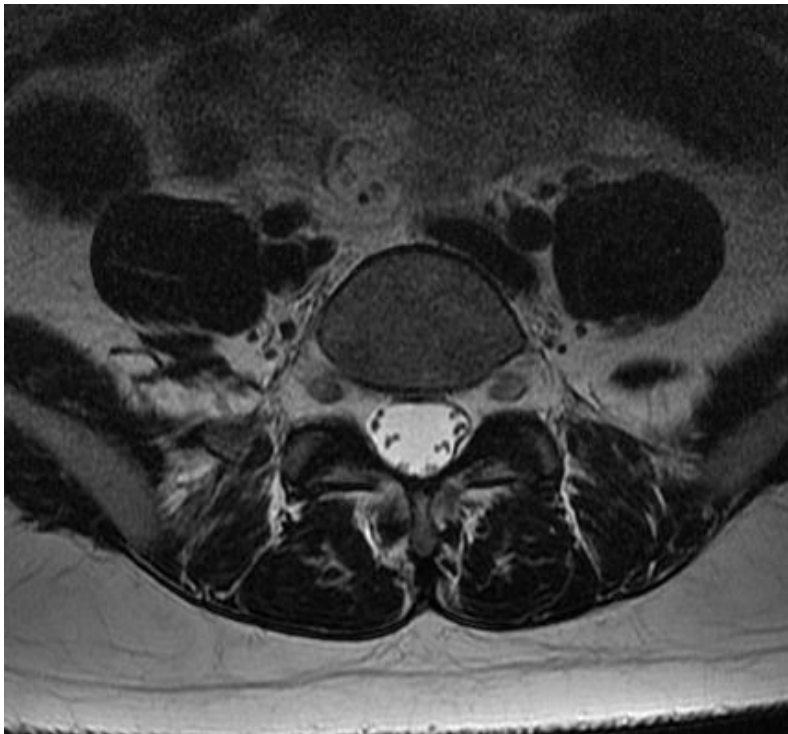
5

## Nomenclature and Classification of Lumbar Disc Lesions

Speaking the same language is foundational for optimized integrated spine care. Physicians need to have a reliable set of terms and criteria that transcend the various specialty jargon. Guided by the need to establish a standardized and universally acceptable classification system for identifying lumbar disc pathology, an interdisciplinary task force created a collective set of guidelines. Again we reference the guidelines that were presented in 2001 through the combined efforts of the North American Spine Society, American Society of Spine Radiology, and American Society of Neuroradiology<sup>1</sup>. All spine practitioners are encouraged to read the original work of this task force located in volume 26, Number 5, Spine 2001.

### Normal

The normal disc is defined as a young hydrated disc that has not shown signs of degeneration or loss of disc height, hydration, bony edema, or degenerative changes.



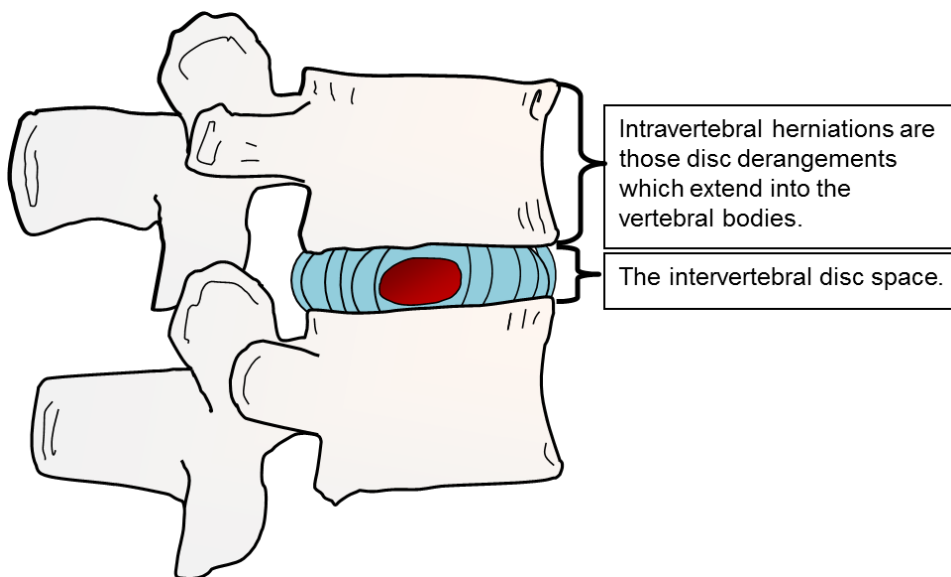
[1] Fardon DF, Milette PC. Nomenclature and classification of lumbar disc pathology: recommendations of the combined task forces of the north American spine society, American society of spine radiology, and American society of neuroradiology. Spine, Volume 26(5).March 1, 2001.E93-E113

# Classification of Lumbar Disc Derangements

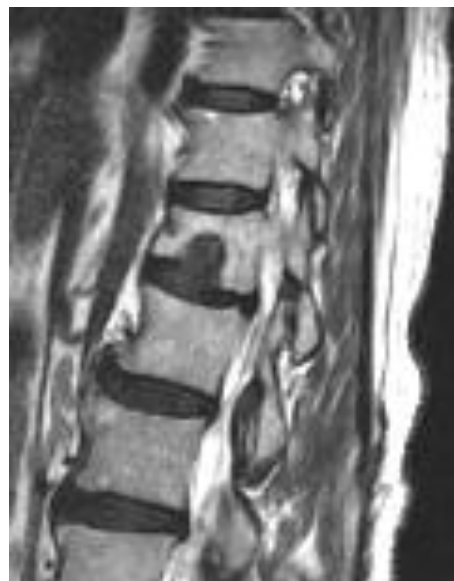## Differentiating Between an Intravertebral Disc Herniation and an Intervertebral Disc Herniation

The *intervertebral* space is the region between two adjacent vertebral bodies. This space is typically occupied by the intervertebral disc. The peripheral boundaries of the intervertebral space is marked by the border of the vertebral body. An intervertebral herniation occurs when disc tissue migrates outside of the intervertebral boundaries.

*Intravertebral* herniations occur when the disc migrates into the vertebral body. This usually occurs with axial compression from trauma, excessive load bearing, or a reduction in the bony integrity of the endplate and underlying cancellous bone. Longstanding intravertebral herniations are usually considered a coincidental finding.



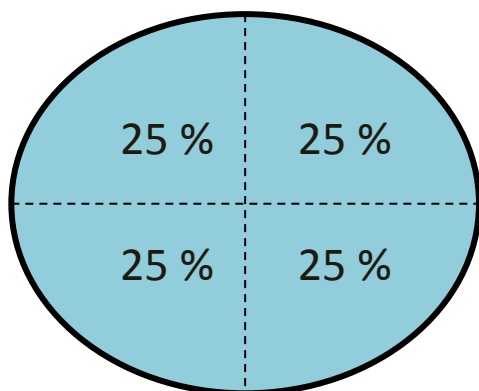
This sagittal T2 weighted image reveals a large intravertebral herniation through the inferior endplate of L1.



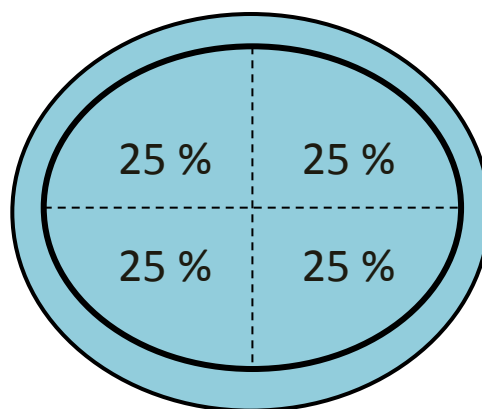
## Classification Parameters of Intervertebral Disc Derangements

To simplify the classification of disc derangements the disc is reduced to a two dimensional oval model that is divided into quadrants. Each 90° quadrant represents 25 % of the total circumference of the disc. Using axial MRI imagery and this simple guideline allows the delineation between broad-based and focal herniations, between symmetrical and asymmetrical disc bulges, and between extrusions and protrusions of the disc.

Normal Disc

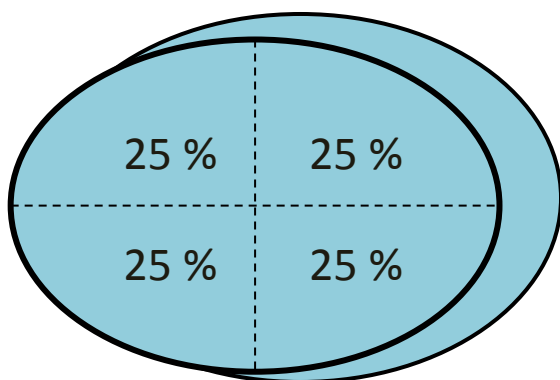


Symmetrical Disc Bulge



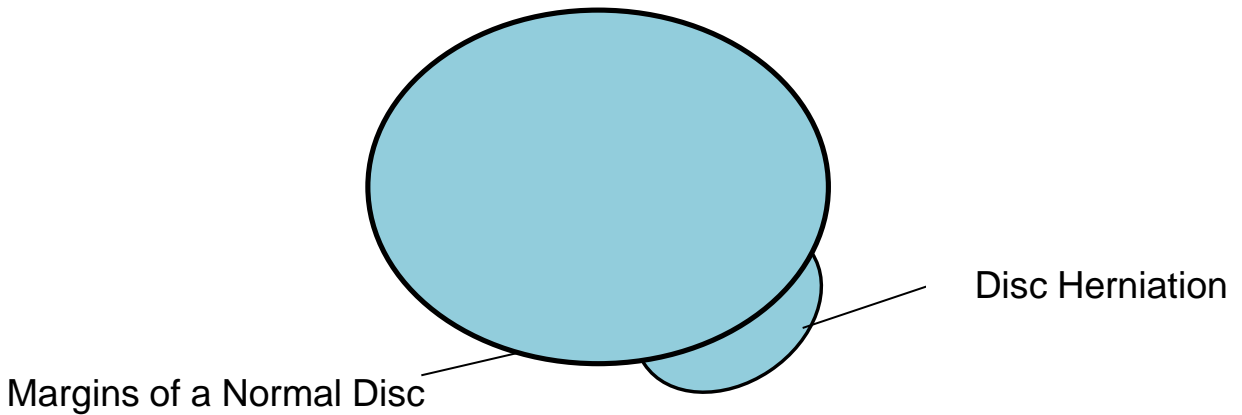
Disc bulges are categorized as disc migration (beyond the boarder of the vertebral apophyses) of more than 50% (180°) of the disc circumference. Symmetrical bulging discs have a symmetrical appearance of bulging between 50 and 100 percent of the disc circumference. The above schematic depicts a symmetrical bulging disc. Disc bulges are not considered a herniation. Herniations, by contrast, are disc derangements which involve less than 50 %of the circumference of the disc.

Asymmetrical Disc Bulge



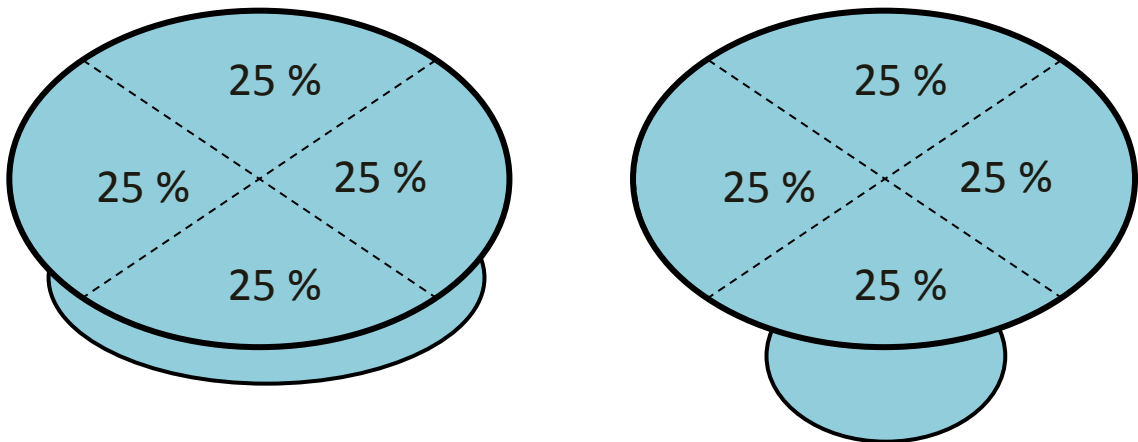
Asymmetrical disc bulges are categorized as disc derangements that are asymmetric but involve outward migration of disc material along at least 50% of the disc's circumference. Asymmetrical bulging discs have an asymmetrical appearance of bulging greater than 50 of the disc circumference. This schematic depicts an asymmetrical bulging disc.

## Disc Herniation



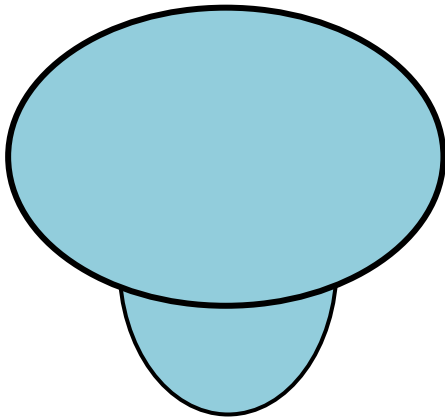
Disc herniations are migrations of disc tissue more localized in appearance, occupying less than 50% of the disc's circumference. There are several subcategories of disc herniation.

### Differentiating between a Focal and a Broad-Based Disc Herniation

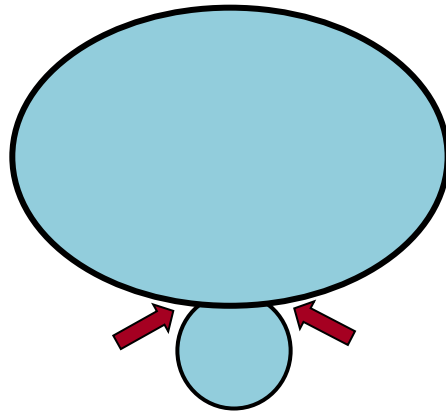


A broad-based herniation occupies 25-50% of the disc circumference. A focal disc herniation occupies less than 25% of the disc circumference. Recall that a disc bulge occupies more than 50% of a disc's circumference.

## Differentiating between a Protrusion and an Extrusion



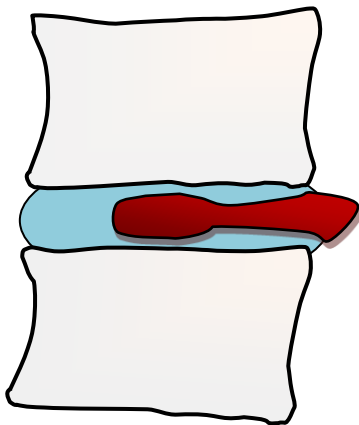
Disc Protrusion



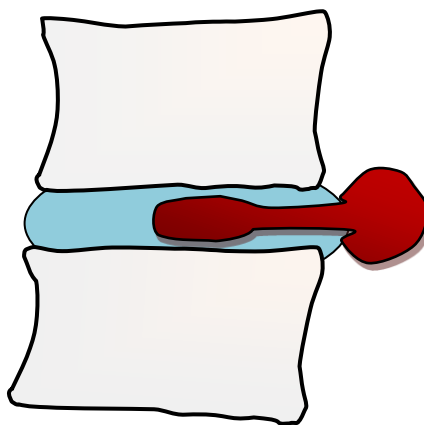
Disc Extrusion

A disc protrusion is wider at the base than it is at the tip. A disc extrusion mushrooms out so that it will have a narrowed waist at the base as indicated by the arrows.

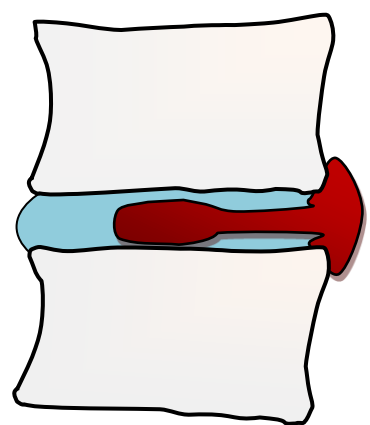
## Sagittal Views of Protrusions and Extrusions



Protrusion



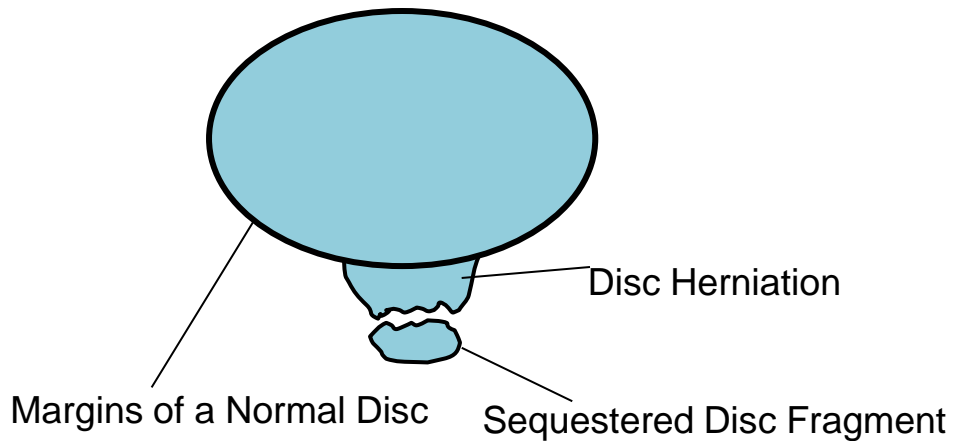
Extrusion



Extrusion

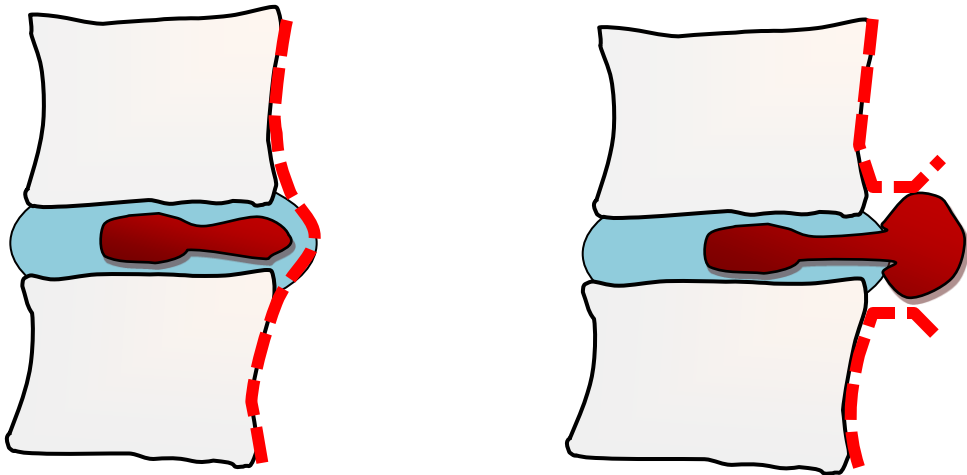
Disc extrusions can be diagnosed in either the axial or sagittal planes. A protrusion is a herniation that has a wide proximal base that narrows as it extends distally from the center of the disc. An extrusion has an expansive herniation that widens after it leaves the intervertebral space. Even if the herniation appears to have a wide base like an protrusion, it is considered an extrusion if it expands along the vertebral body to a width wider than the disc (see image on right). A protrusion does not exceed the cranio-caudal boundaries of the intervertebral disc.

## Sequestered Fragment



Another category of disc extrusion is the sequestered fragment. A sequestered fragment is the designation given to a disc derangement in which a portion of the disc breaks free from the rest of the disc. Sequestered fragments can migrate from their mother discs. They are considered a category of disc extrusions.

## Contained versus Non-contained Herniations

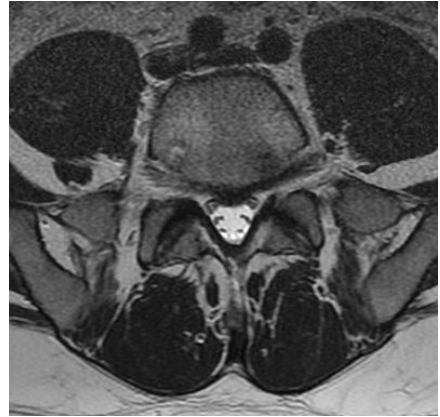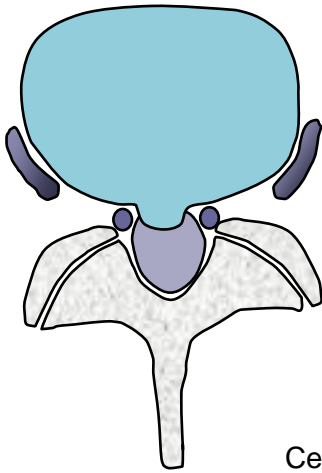


Sub-Ligamentous and Contained)

Extra-ligamentous and Non-Contained

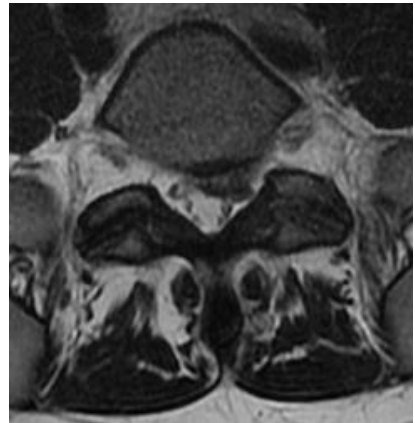
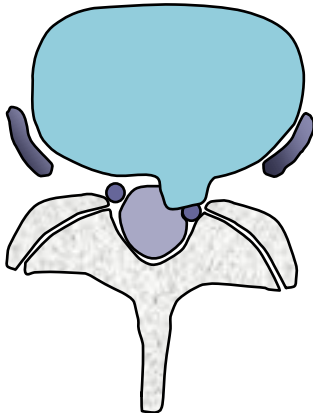
Another identifier describing disc derangements is the relationship of the derangement to the outer annulus and the posterior longitudinal ligament (PLL). The PLL lies over the posterior vertebral bodies and the posterior portion of the disc. If the PLL and the outer annulus is intact and contains the disc derangement, it may be categorized as a sub-ligamentous or contained herniation. If the disc has violated the outer annulus, it is categorized as a non-contained herniation. If the disc derangement disrupts and passes through the posterior ligaments it has been called an extra-ligamentous herniation. The current limitations of MR often make it difficult to differentiate between ligamentous, contained and non-contained herniations.

## Central Disc Herniation

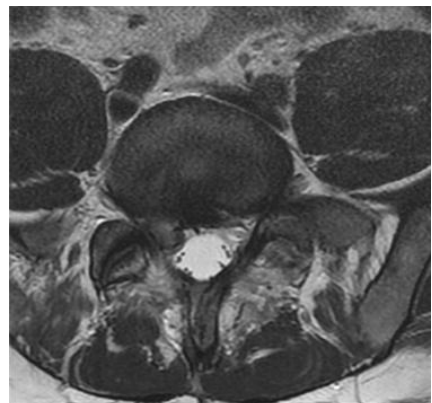
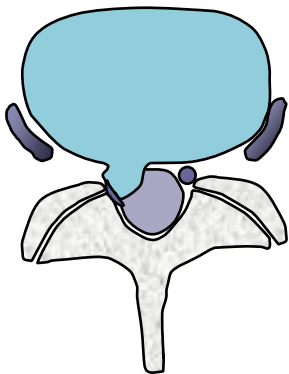


Central disc derangement without contacting the nerve roots.

## Para-central herniation displacing a nerve root



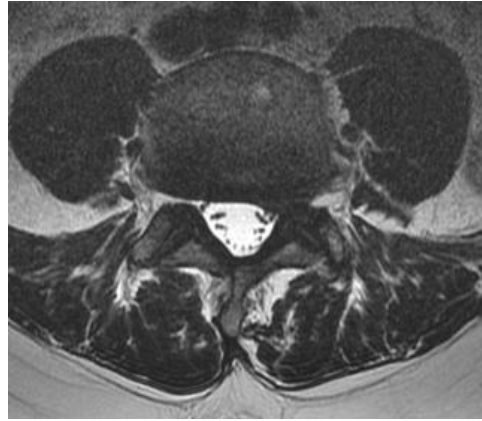
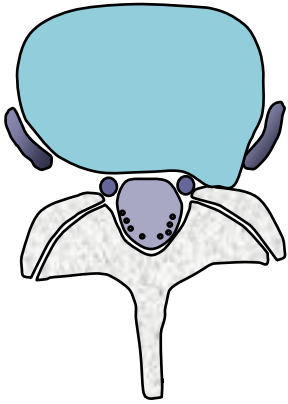
## Nerve Root Compression



This MRI demonstrates a herniation that contacts and displaces the S1 nerve root, compressing the nerve root against the bony posterior portion of the spinal canal.

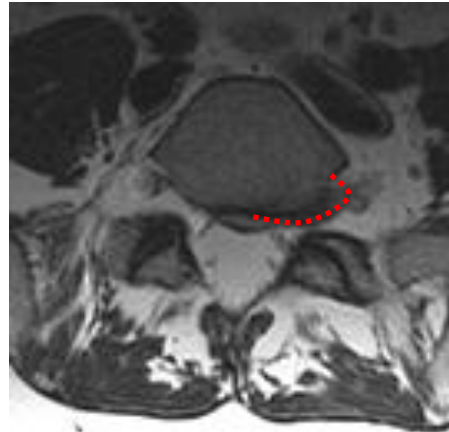
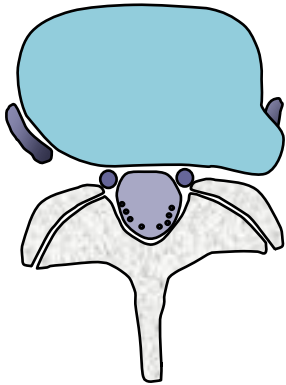


## Foraminal Disc Herniation



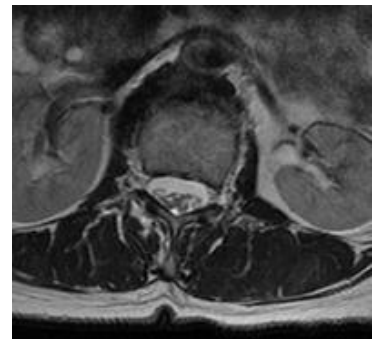
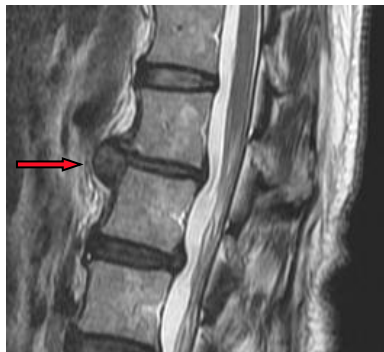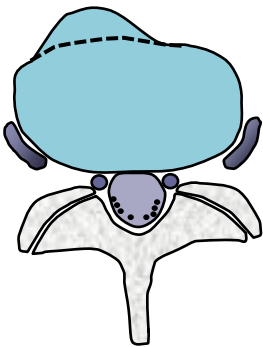
A herniation into the foraminal canal can compromise the exiting nerve roots. Even a small herniation in the foraminal canal can cause significant nerve impingement.

## Far-Lateral Foraminal Disc Herniation



Far-lateral herniations may contact and affect the exiting nerve root after it leaves the intervertebral foramen. The image on the right outlines the circumference of this far-lateral herniation that can be visualized in both images.

## Anterior Disc Herniation



Anterior disc herniations do not compromise the spinal cord, thecal sac, or nerve roots, but may be a source of pain and be indicative of biomechanical failure.

# **Classification of Annular Tears**

---

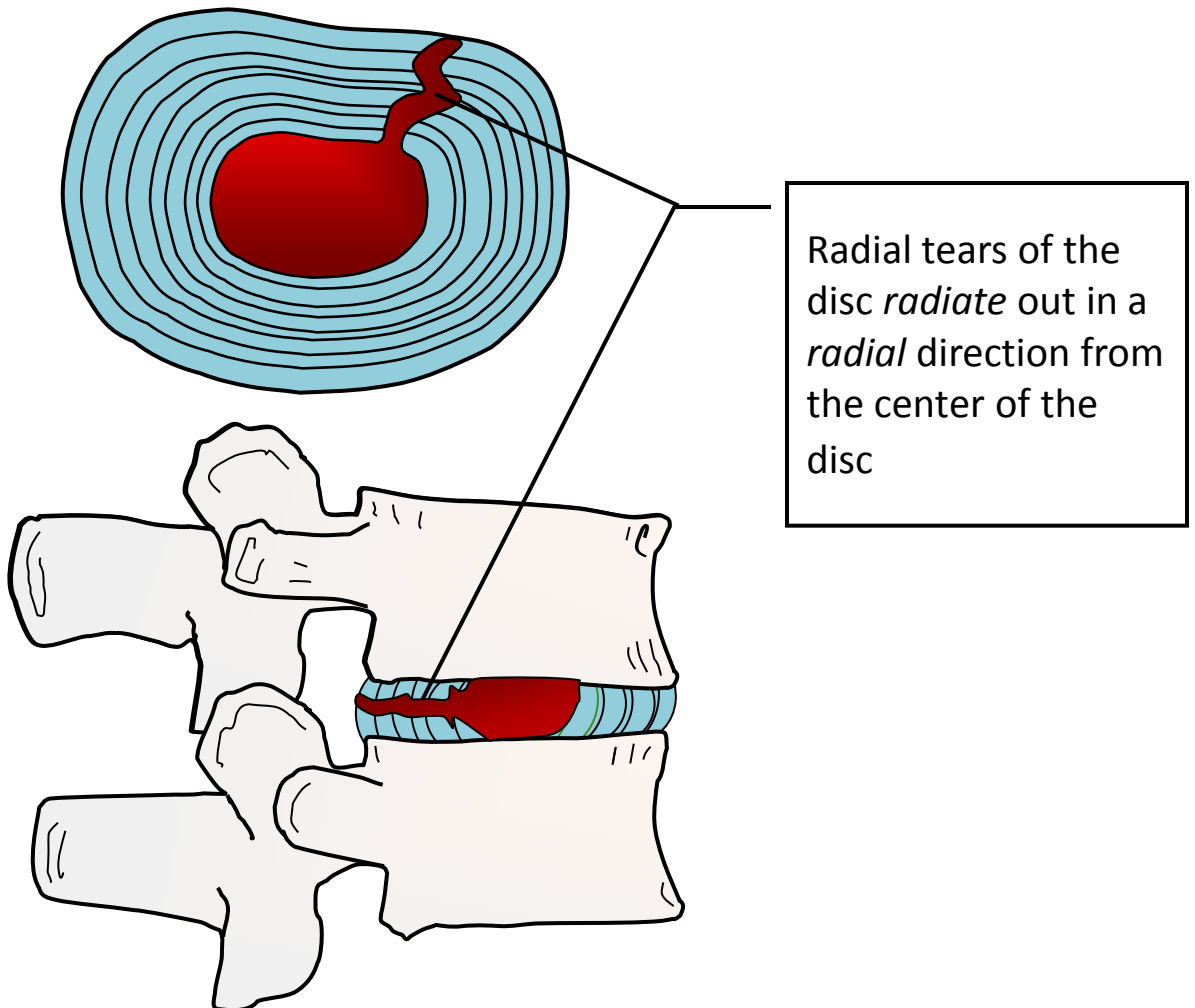
6

## Annular Tears

The term annular tear or annular fissure is used to categorize separation between the annular fibers, avulsion of the fibers from the vertebral body, or a tear through the fibers. A common misconception is that trauma is always indicated in a tear. Annular tears may occur from trauma or over time as part of a degenerative process. Some experts prefer the term annular fissure since it is less implicative of trauma. There are three categorizations of annular tears: radial tears, transverse tears, or concentric tears. Annular tears may be clinically significant or may be asymptomatic coincidental findings. As with many findings on MRI, just because a lesion is visible does not mean that it is clinically significant.

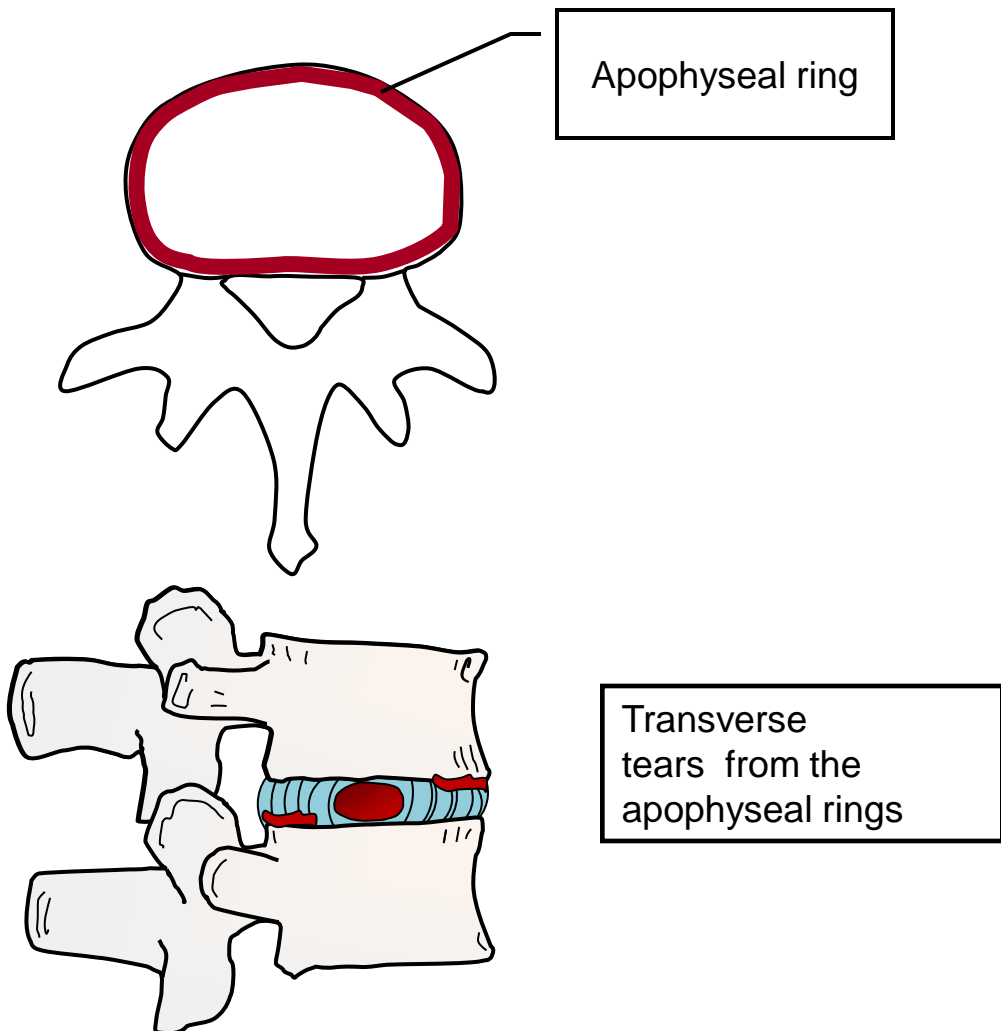
### Radial Tears

*Radial tears* are tears that begin centrally and progress outward in a radial direction. Radial tears may precede the migration of nucleus material radially resulting in a disc herniation.



## Transverse Tears

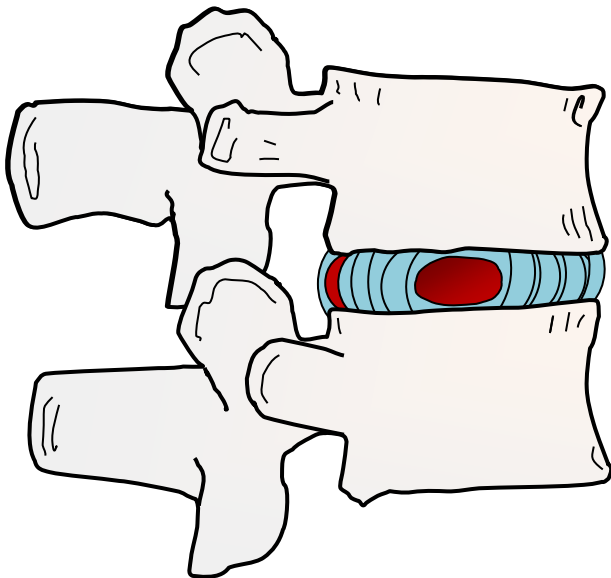
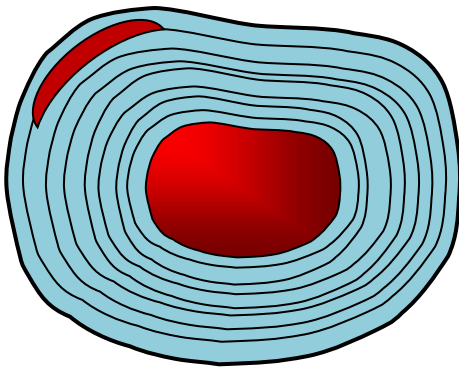
Transverse tears have also been called rim lesions. Transverse tears are horizontal lesions that may involve the disc tearing away from the endplate. This lesion may involve disruption of Sharpey's fibers (the matrix of connective tissue that binds the disc to the vertebral endplates) and the disc. Transverse tears appear to have a causal effect in degenerative disc disease and the formation of osteophytic spurring. They are typically small and limited to the joining of the annular attachments to the apophyseal ring –the rim of the vertebra, hence the term Rim Lesion.<sup>1</sup>



1. Schmorl G, Junghans H, "The human spine in health & disease". New York: Grune & Stratton, 1971

## Concentric Tears

Concentric tears are a separation of the concentric annular bands that surround the nucleus. Normally the outer 1/3 of the annulus is affected by concentric tears. Incidentally, it is the outer 1/3 of the annular fibers that are the most richly innervated and susceptible to nociception.



Concentric tears are tears that separate bands of the annular rings of cartilage. They are characterized by high intensity zones (white appearance) on T2 weighted images. Most concentric tears occur in the outer portion of the intervertebral disc.

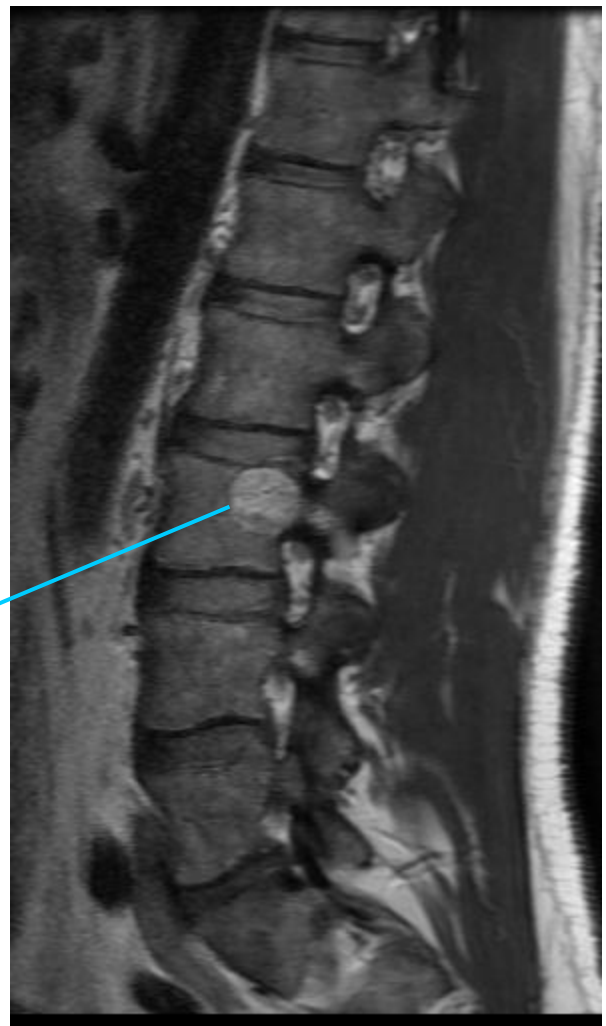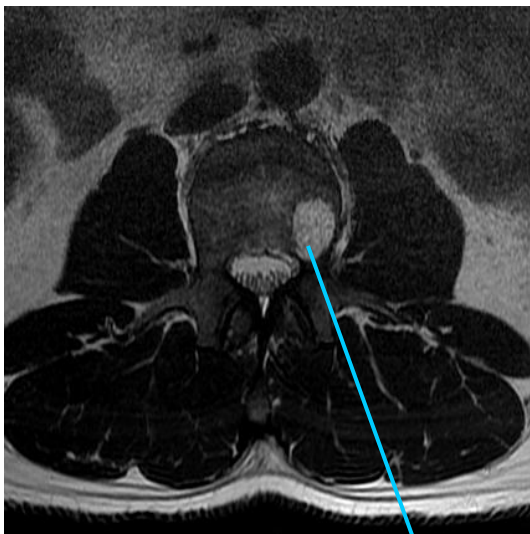
# Hemangiomas

---

7

## Hemangiomas

Being able to discern the difference between neoplasms and predominantly benign findings such as hemangiomas is a valuable skill. Hemangiomas are common, so common that it is easy to become complacent and flippantly identify all intravertebral findings as hemangiomas. Being familiar with common incidental findings will add confidence to the provider and help in identifying what is not normal. Also it is the clinician reviewing MRs with patients (versus the radiologist) who will be confronted with a startled patient gawking at a large scary looking hemangioma during a report of findings.

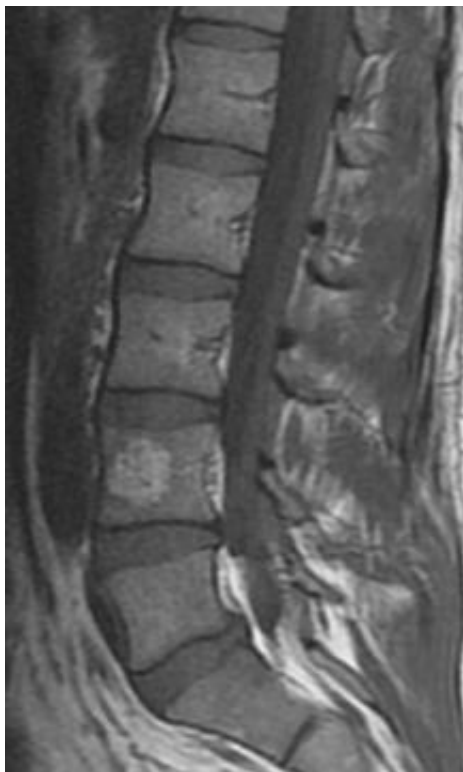

Hemangioma

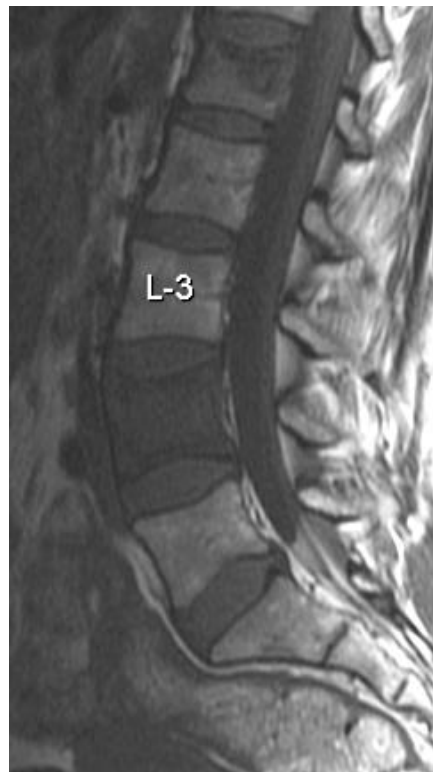# Differentiating between Vertebral Body Metastases and Hemangiomas

Any discussion about the differentiation between benign and cancerous lesions on MRI should occur over the safety net provided by radiologists. Hemangiomas are a common benign finding on lumbar MRI. Hemangiomas are usually incidental and asymptomatic. Upon first viewing of a large hemangioma on MR a clinician may be taken back by the appearance of this impressive looking lesion. Having confidence in the differentiation of these two findings will expedite appropriate progression of care.

| Lesion Type | T1     | T2     | T2 with Fat suppression |
|-------------|--------|--------|-------------------------|
| Hemangiomas | Bright | Bright | Dark                    |
| Metastases  | Dark   | Bright | Bright                  |



**Image 1.** This T1WI shows a bright hemangioma within the anterior body of L4



**Image 2.** Metastasis is seen at two levels, L1 and L4, in this T1WI. Note the darkness of the entire vertebral body of L4 in this T1WI.



# **Spondylolysis and Spondylolisthesis**

---

8

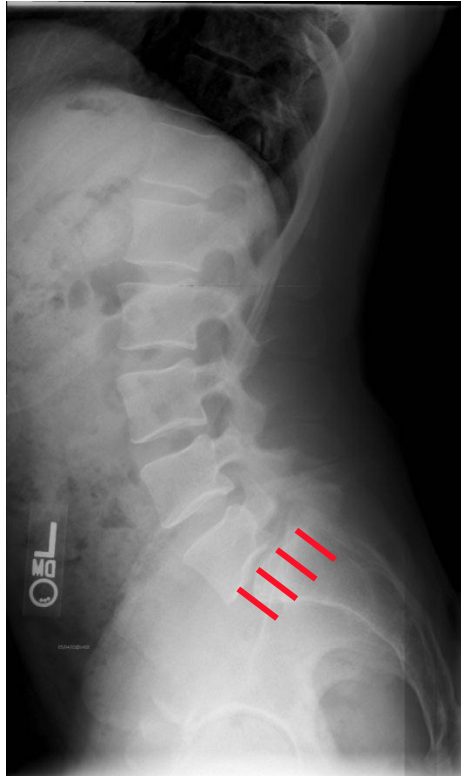## Types of Spondylolisthesis

Spondylolisthesis is a condition in which one vertebra slips anteriorly on the vertebra below. While five types of spondylolisthesis have been identified, this chapter will concentrate on the two most common types: degenerative and isthmic.

The various types of spondylolisthesis share the commonality of anterior vertebral slippage, but have significantly different etiologies and clinical presentations. It is important to be able to differentiate the difference and to be familiar with their radiographic presentations. This chart clarifies the main differences between the categories of spondylolisthesis:

| <b>Types of spondylolisthesis</b> | <b>Pathology</b>  |
|-----------------------------------|---|
| Degenerative                      | Facetal and connective tissue degeneration leading to anterior listhesis                          |
| Isthmic                           | Secondary to spondylolysis of the affected pars interarticularis                                  |
| Congenital                        | Usually from hypoplasia of the S1 facets  |
| Traumatic                         | Resulting from an acute fracture that may include structures other than the pars interarticularis |
| Post surgical                     | Surgical mishaps that progress or cause a spondylolisthesis                                       |

## Meyerding Classification System



**Image 1.** Grade I spondylolisthesis of L5 on S1 viewed on a lateral plain film radiograph.

MRI is not the preferred medium for viewing and identifying a spondylolisthesis. X-ray (particularly weight bearing views) and CT are preferred to MRI for visualizing spondylolisthesis. While spondylolysis and spondylolisthesis may be diagnosed and graded on a lateral X-ray, the preferred image for identifying a spondylolysis is the oblique plain film x-ray. MRI, however, is a valuable tool for determining the effect of spondylolisthesis on the soft tissues of the spine and adjoining structures.

To categorize the degree of anterior slippage of a spondylolisthesis, the Meyerding classification system was adopted. The Meyerding grading scale grades a spondylolisthesis (regardless of the cause of the listhesis) on a scale of 1-4<sup>1,2</sup>. Each number represents 25% of the superior end plate of the vertebra or sacral segment below the level of listhesis. When the posterior body of L5 slides forward up to 25% of the surface of the vertebra below, it is classified as a Grade I, 25-50 % Grade II, 50-75% Grade III, and 75-100% Grade IV. If the vertebral body slides completely off of the segment below, it is called a spondyloptosis.

Clinical note: If a spondylolisthesis exceeds grade I (greater than 25% anterior slippage), it will have a spondylolysis. Degenerative spondylolisthesis cannot exceed 25% anterior listhesis.

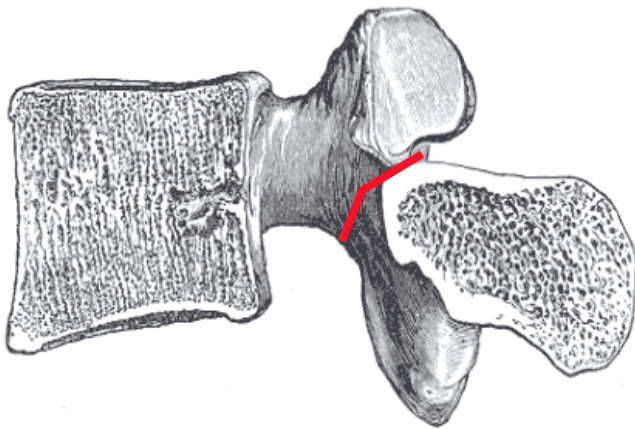
<sup>1</sup> Meyerding HW: Spondylolisthesis. Surg Gynecol Obstet 54:371-377, 1932

<sup>2</sup>McPhee B: Spondylolisthesis and spondylolysis, in Youmans JR (ed): Neurological Surgery: A Comprehensive Reference Guide to the Diagnosis and Management of Neurosurgical Problems, ed 3. Philadelphia: WB Saunders, 1990, Vol 4, pp 2749-2784

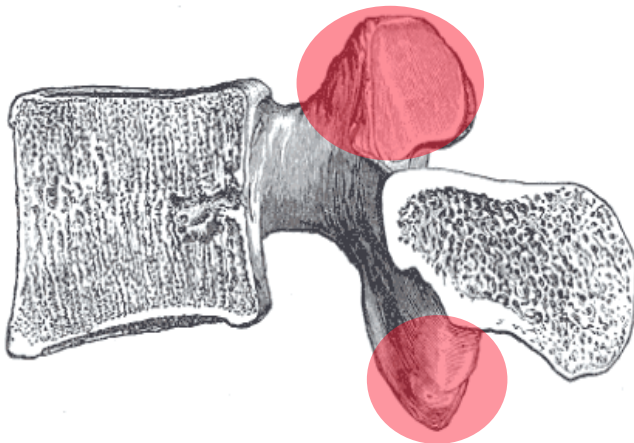
## Comparing Isthmic and Degenerative Spondylolistheses

An isthmic spondylolisthesis is characterized by a bilateral pars interarticularis defect or stress fracture (spondylolysis) that essentially splits the vertebra into two pieces.

In the degenerative variety of spondylolisthesis, the posterior elements of the vertebral segments degenerate to the point that they cannot prevent anterior listhesis (slippage). this results in an anterior listhesis of the entire vertebral body along with the posterior elements of the vertebra.



Isthmic spondylolisthesis occurs after a specific bony insult occurs. A stress fracture (though this terminology has been disputed) of the pars interarticularis, also known as a spondylolysis, occurs as a result of repeated stresses or microtrauma.

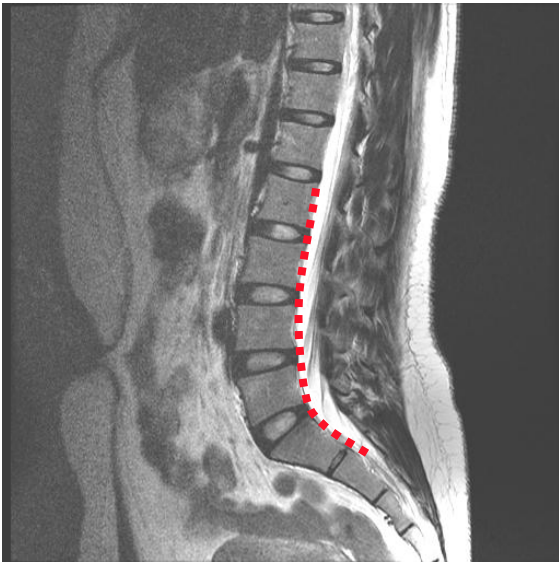


Degenerative spondylolisthesis is by far more common in the general population (though less common in younger populations). Degenerative spondylolisthesis occurs over time, secondary to degenerative changes of the facet joints, discs, and subsequent ligament laxity.

Images adapted from Henry Gray (1821–1865). Anatomy of the Human Body. 1918.

## The Characteristics of a Spondylolisthesis in Sagittal Images

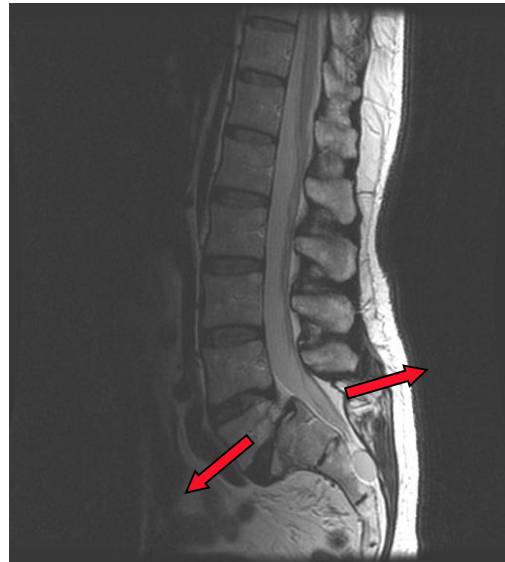
In addition to the primary radiographic findings of pars interarticularis defects and anterior listhesis of the vertebral body, there are other secondary findings that are characteristic of spondylolisthesis.



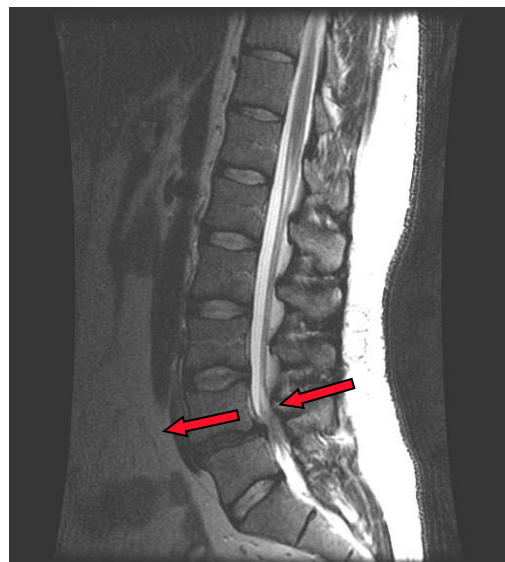
**Image 1.** A normal spine will have a continuous uninterrupted alignment of the vertebral segments

Image 1 shows a normal spine without anterior listhesis. The red dotted line traces the posterior longitudinal ligament and posterior vertebral bodies revealing a normal lumbar lordosis.

Bilateral pars interarticularis spondylolysis literally breaks the vertebra into two pieces. When a spondylolysis progresses to a spondylolisthesis, it is common for the vertebral body to travel anterior, and the posterior elements to list posterior (Image 2). In contrast, a degenerative spondylolisthesis will have the entire vertebra travel anterior. While an isthmic spondylolisthesis may expand the central canal, a degenerative spondylolisthesis will frequently contribute to a stenosis of the central canal. This concept is expanded upon on the following page.



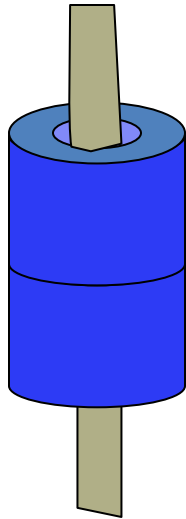
**Image 2.** An isthmic spondylolisthesis may have a separation of the two segments of the vertebra. These segments may migrate in opposite directions (red arrows).



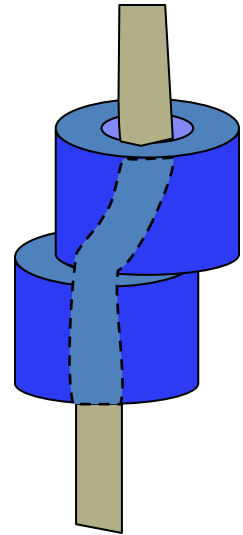
**Image 3.** Degenerative spondylolisthesis has the entire vertebra moving anterior as a unit. Degenerative spondylolisthesis will not progress past 25 %.

## Conceptualizing the Effects of Spondylolisthesis on the Central Canal

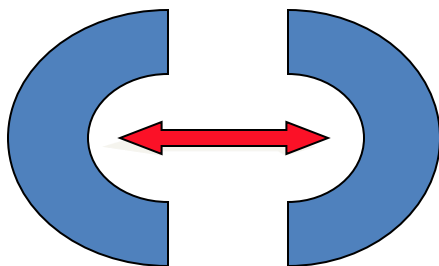

**Figure A.** This schematic shows the thecal sac descending through the spinal canal in a normal matter.



**Figure B.** When a degenerative spondylolisthesis occurs, the thecal sac is distorted as it follows the snaking central canal.



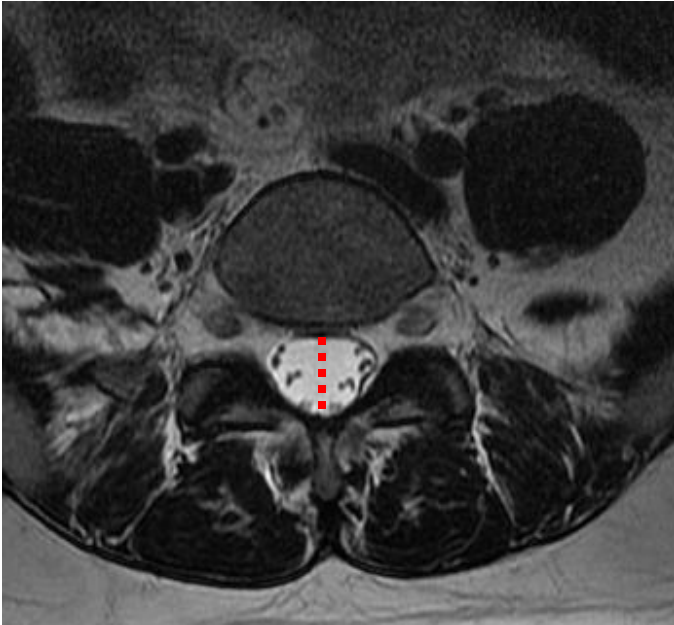
**Figure C.** In degenerative spondylolisthesis the vertebral arch is preserved causing a canal narrowing as the alignment of the canal is compromised. This is often compounded by the stenotic effects of degeneration and ligamentum flavum hypertrophy. Degenerative spondylolisthesis is often associated with a clinical presentation characteristic of central canal stenosis. This image depicts the compromised alignment of the two adjoining vertebra from above. The canal appears narrowed when viewed from above.



**Figure D.** When a bilateral spondylolysis is present, the vertebral arch is not preserved. The two components of the vertebra may open causing a widening of the canal.

These images are an attempt to simplify the understanding of the effects of degenerative and isthmic spondylolisthesis on the central canal of the spine. Simply put, degenerative spondylolisthesis generally results in central canal stenosis, and isthmic spondylolisthesis expands the central canal at the level of the lysis.

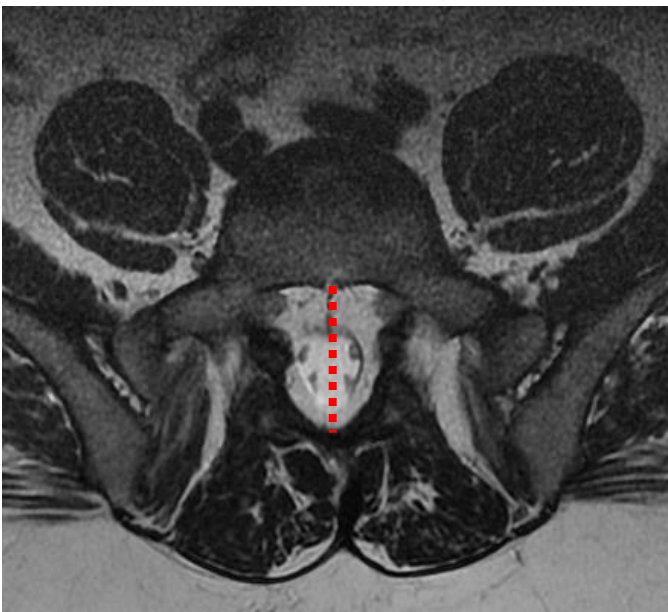
## The Characteristics of a Spondylolisthesis in Axial Images



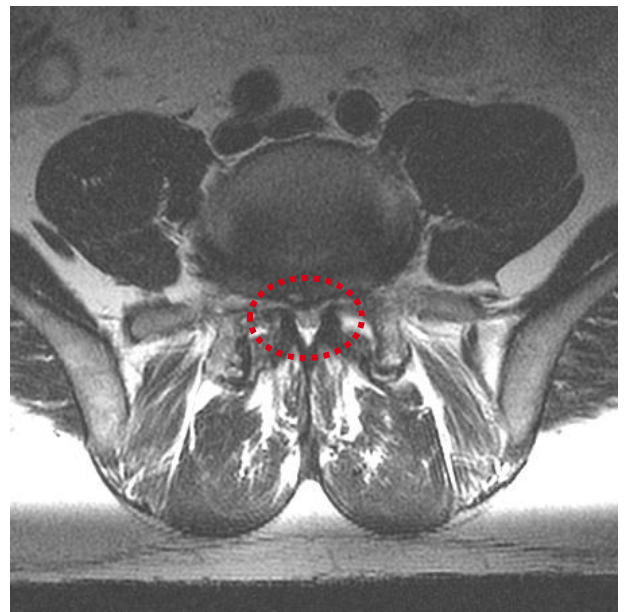
**Image 1.** Normal size central canal.

The central canal of the lumbar spine is typically oval shaped (Image 1). In an isthmic spondylolisthesis with a defect of the pars interarticularis, the body of the vertebra moves anterior while the posterior arch migrates posterior. This elongates the canal into an aberrant appearance (Image 2). Note the gap between the posterior vertebral body and the anterior thecal sac in image 2.

Degenerative spondylolisthesis, by contrast, is frequently characterized by a reduction in canal size (Image 3). Axial imagery can aid in identifying the type of spondylolisthesis and its effects on other structures.

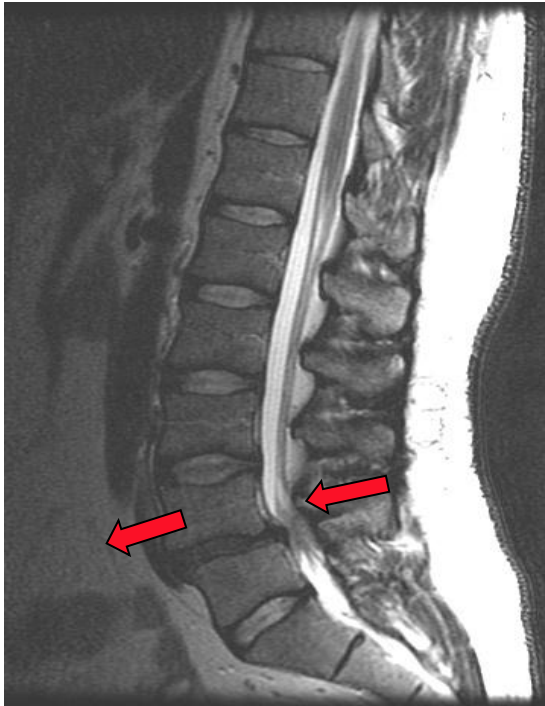


**Image 2.** Elongated central canal. This finding is characteristic of an isthmic spondylolisthesis.

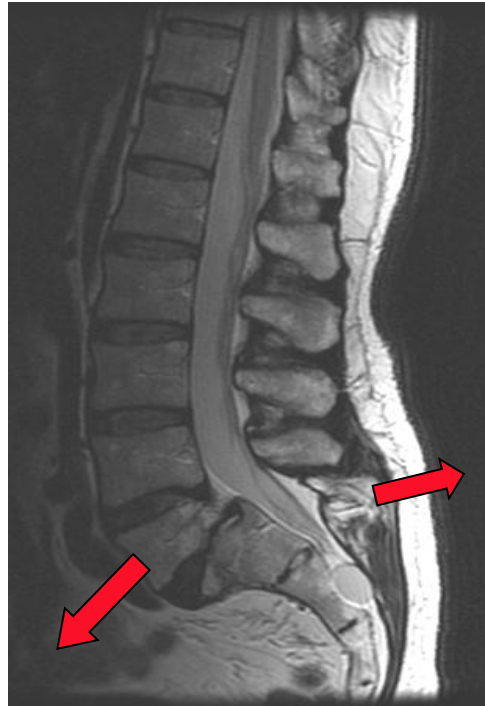


**Image 3.** Stenotic central canal. This finding is characteristic of a degenerative spondylolisthesis.

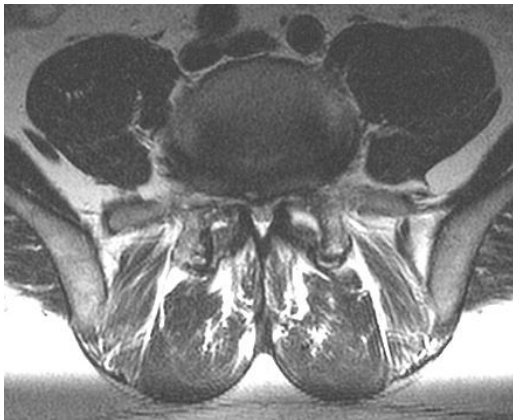These T2W MRIs correlate axial images with sagittal images. These images clearly show the central canal stenosis associated with degenerative spondylolisthesis (images 1 and 2). This stands in stark contrast to the isthmic spondylolisthesis which is characterized by the elongated canal visualized on the axial image (images 3 and 4).



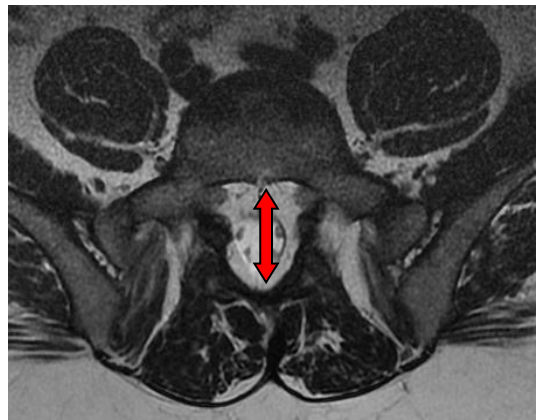
**Image 1.** Sagittal image of a degenerative spondylolisthesis of L4 on L5. The entire vertebra slips forward.



**Image 3.** Sagittal image of an isthmic spondylolisthesis of L5 on the sacrum. The anterior and posterior elements travel in opposite directions.



**Image 2.** Axial image of degenerative spondylolisthesis with severe central canal stenosis and facet effusion.

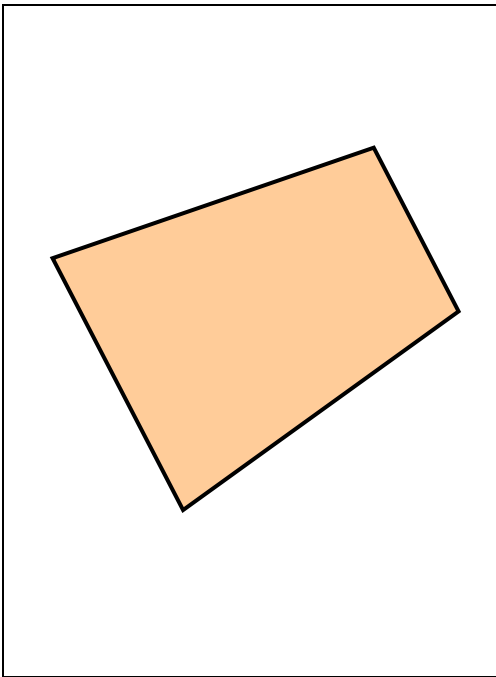


**Image 4.** This axial image reveals an elongated central canal as the vertebral elements migrate away from each other.

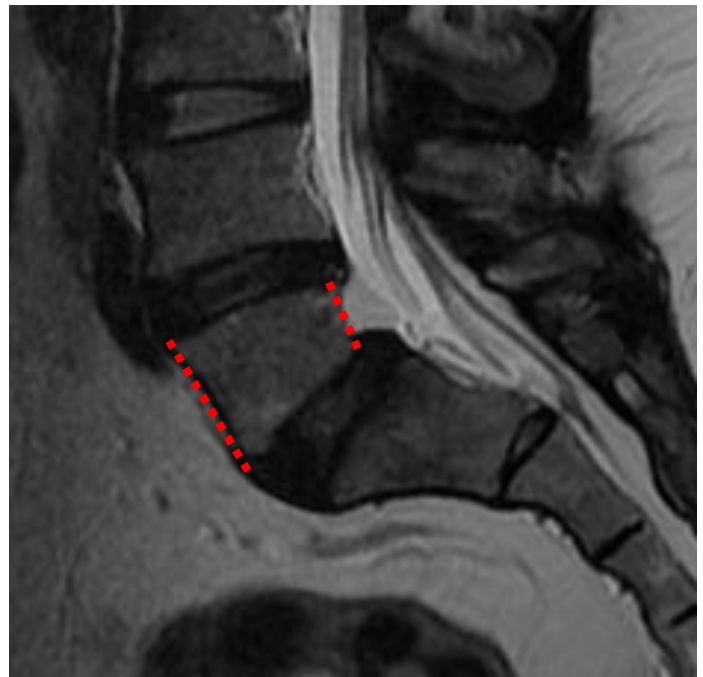

## Wedging of Vertebral Body Secondary to Isthmic Spondylolisthesis

Finding a wedged lumbar vertebra, particularly at L5, is associated with spondylolisthesis secondary to spondylolysis. While it is not fully understood if this finding predisposes the vertebra to lysis or if it occurs as a result of lysis and listhesis, experts are leaning toward the thought that this trapezoid deformation occurs over time after the spondylolysis and listhesis occur.



**Image 1.** Trapezoid shape.



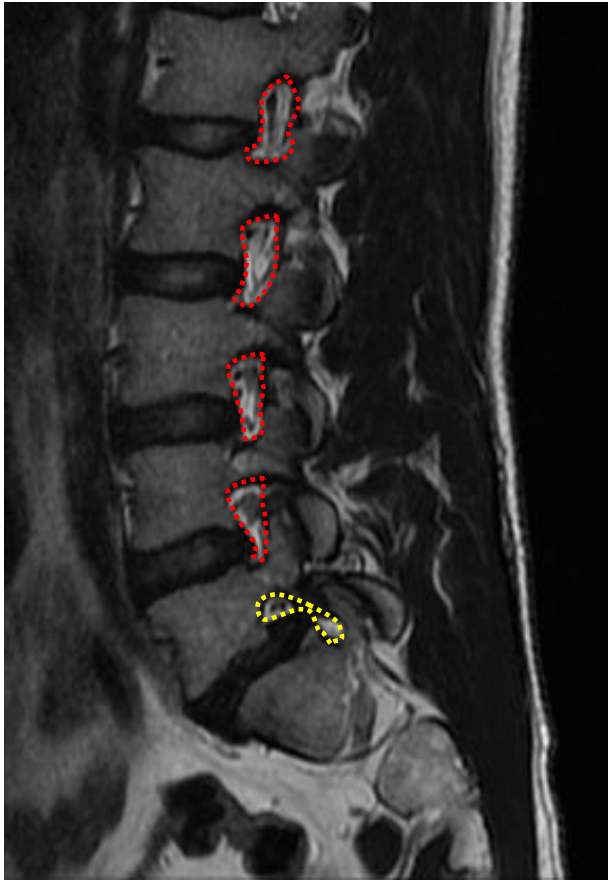
**Image 2.** The vertebra affected by the lysis has a tendency to take on a trapezoid shape. This phenomenon is not pathognomonic for an isthmic spondylolisthesis, but is a point of reference that may point the clinician to a spondylolisthesis.

Antoniades SB, Hammerberg, KW, DeWald, RL. Sagittal plane configuration of the sacrum in spondylolisthesis. *Spine*: 1 May 2000. Volume 25, Issue 9, pp 1085-1091

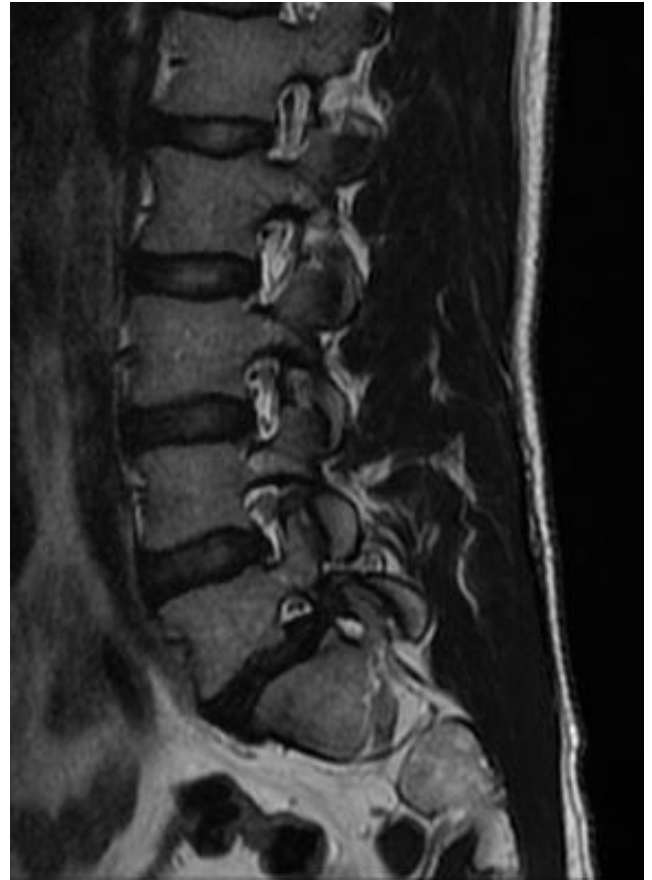
Sim GPG, Vertebral contour in spondylolisthesis. *British Journal of Radiology* (1973) 46, 250-254

<http://bjr.birjournals.org/cgi/content/abstract/46/544/250>

## Characteristics of the IVF in Spondylolisthesis



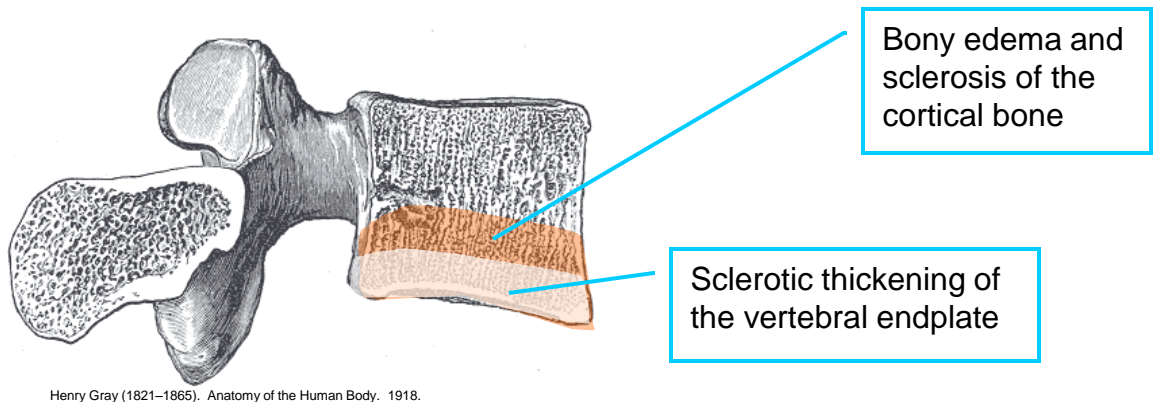
**Image 1**



**Image 2**

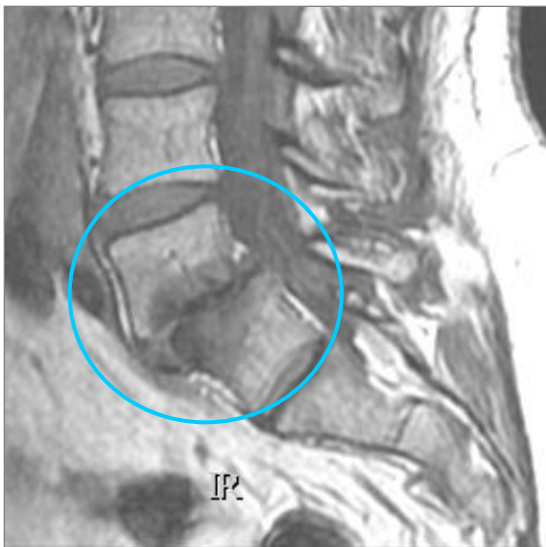The normal outline of an intervertebral foramina (IVF) tends to be shaped like a peanut. Note the shape of the upper IVFs outlined in red dashes in Image 1. In contrast, the L5–sacrum IVF, outlined by a yellow dashed line is contorted due to the anterior slippage of L5. This contortion is representative of a reduction in the size of the IVF resulting in foraminal stenosis. Image 2 shows the same T2W sagittal image without the dashed lines.

Inflammatory and degenerative changes to the endplates and adjoining bone of the vertebra frequently accompany spondylolisthesis. These secondary degenerative changes are visible on MRI. The changes are named after the well-published radiologist Michael T. Modic. Image 1 is a schematic revealing the appearance of Modic degenerative changes on MRI.

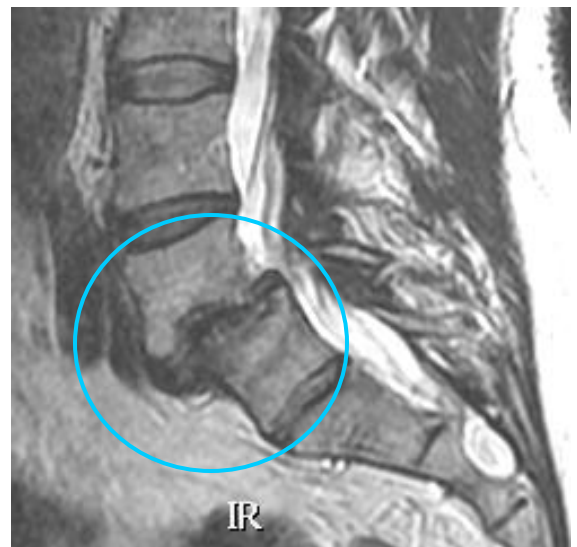

**Image 1.** Modic schematic

Bony edema, disc degeneration, and sclerotic changes to the vertebral endplates secondary to spondylolisthesis are clearly visible in Image 2 and 3.

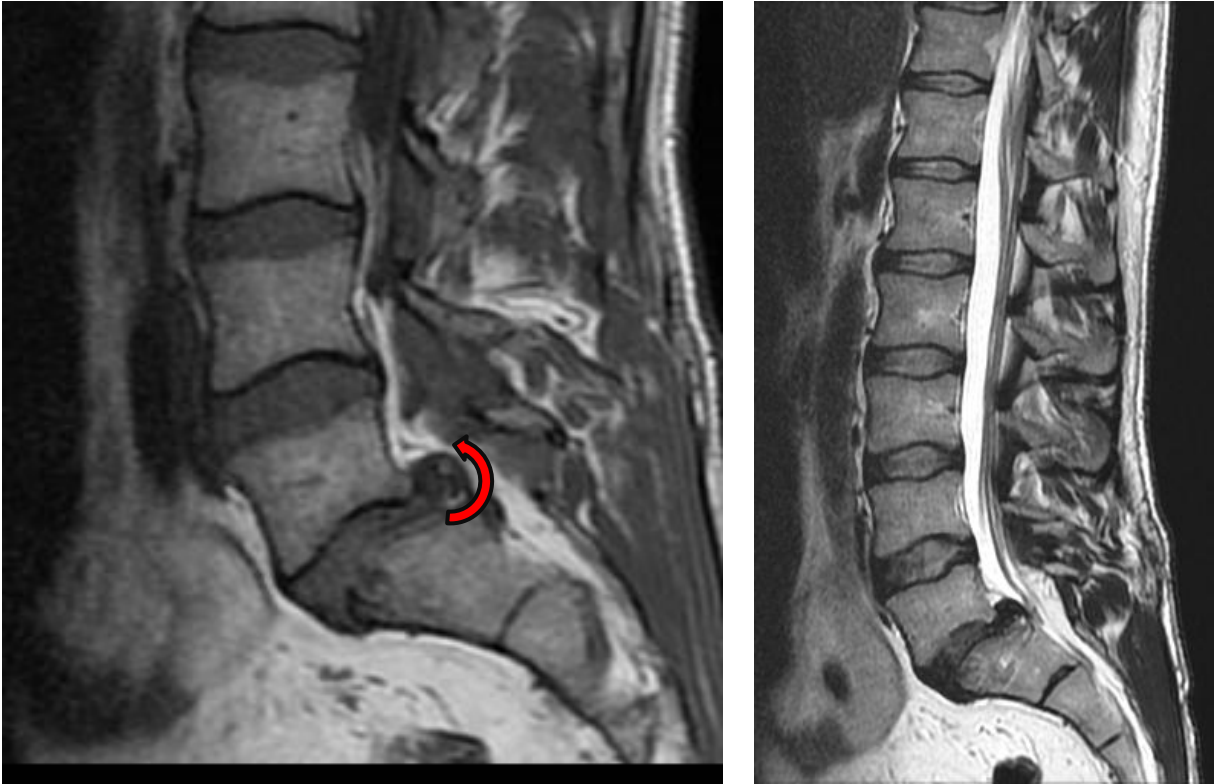


**Image 2.** T1W sagittal image

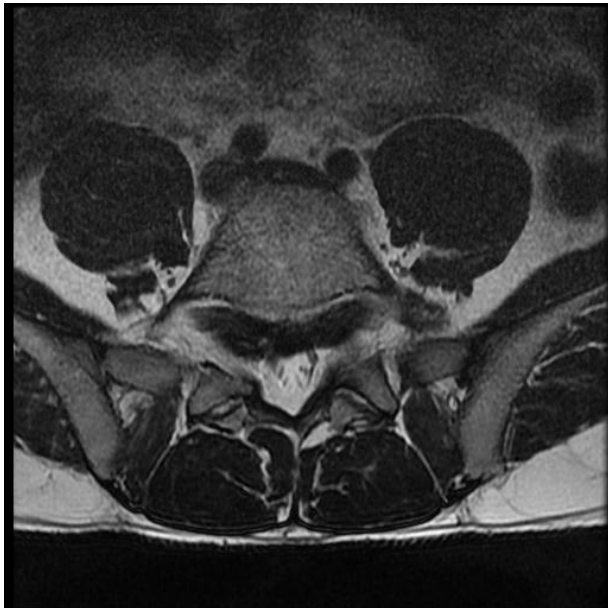

**Image 3.** T2W sagittal image

## Disc Roll-up



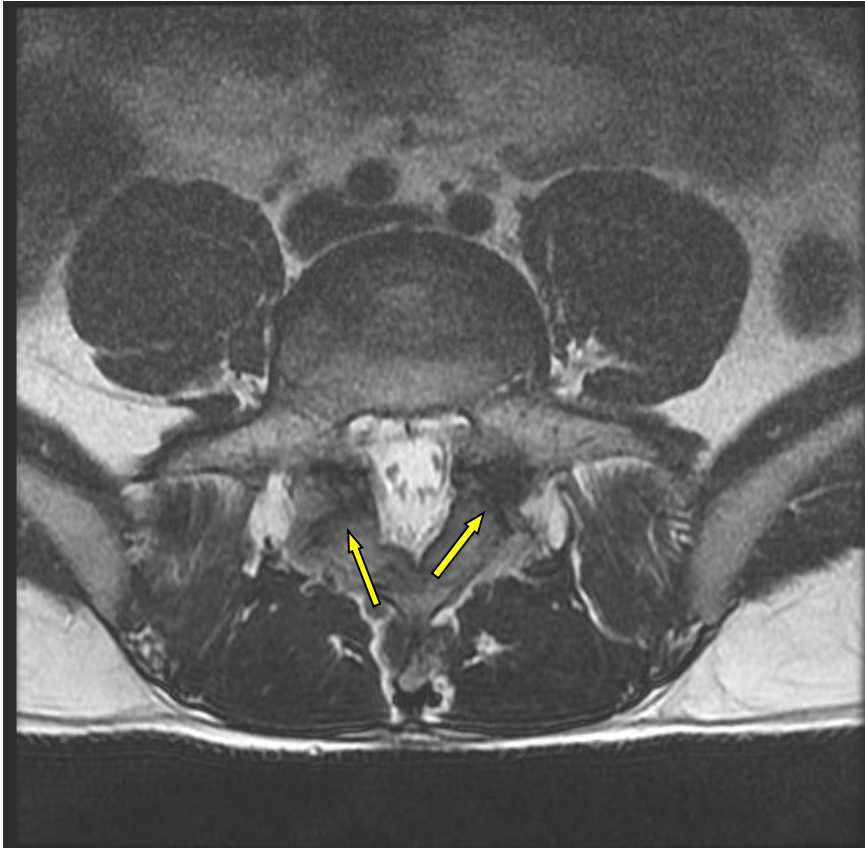
**Image 1 and 2.** L5-S1 spondylolisthesis with disc roll-up.



**Image 3.** Axial T2WI of a spondylolisthesis disc roll-up.

Another common finding in isthmic spondylolisthesis is the “rolling up” or “peeling” of the disc below the listhesis, and less common is the rolling down of the disc above the spondylolisthesis. This disc migration can contribute or cause a stenosis of the IVF.

## Pars Defect



This T1W axial image reveals evidence of a pars defect. MRI reveals bony edema and soft tissue changes, but does not reveal discrete injury to bone. X-ray and CT are preferred for viewing bony injuries.

### Upright, Functional, and Dynamic MRI and Spondylolisthesis

One of the criticisms directed at using standard MRIs for evaluating spondylolisthesis is that the patient is lying supine during the MRI. Lying supine will allow a mobile segment to settle into a lower state of displacement. One study of 510 patients with lower back pain revealed that supine MRI missed 18.1% of spondylolisthesis that were observed in dynamic (flexion) MRIs.<sup>1</sup> As more upright and functional MRI units are made available, this diagnostic medium may replace the neutral/supine MRI for visualizing functional and anatomical disruptions of the lumbar spine.

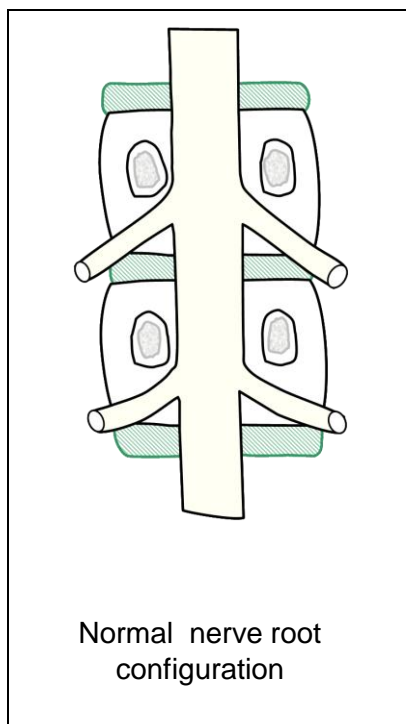
<sup>1</sup> Hong SW, et al., Missed spondylolisthesis in static MRIs but found in dynamic MRIs in the patients with low back pain. *The Spine Journal*, 7 (2007) p 69S

# Conjoined Nerve Roots

---

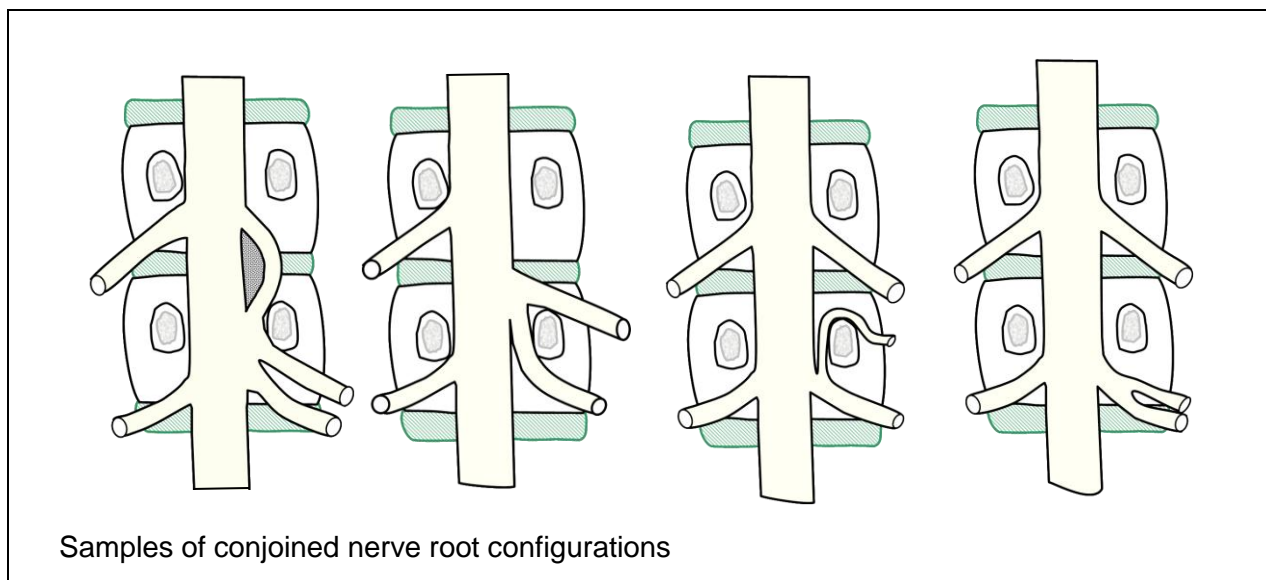
9

## Conjoined Nerve Roots



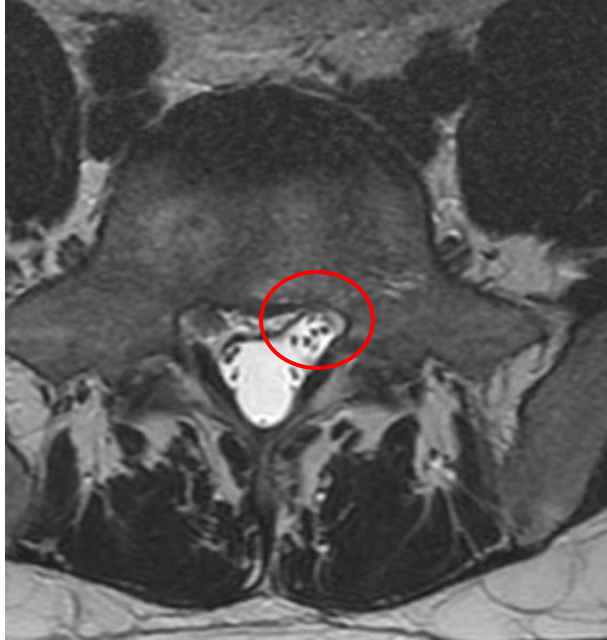
Identifying conjoined nerve roots can be difficult for even skilled radiologists, but since they are periodically left out of radiology reports it is important that spine practitioners learn how to identify the location and clinical significance of conjoined nerves. Anchoring or tethering the nerve roots or the cord into a position of lesion is one of the most disturbing aspects of a conjoined nerve root. Though most conjoined nerve roots will not be symptomatic, symptoms may develop if the conjoined nerve tethers a nerve root into a herniation, stenosis or other compressive lesion.

The nerve roots normally exit the intervertebral foramina in the upper 1/3 of the foramina. If a conjoined nerve tethers a nerve root so that it exits the lower portion of the foramina, it is much more susceptible to the pressure of a disc herniation, facet hypertrophy, or foraminal stenosis. This can create a clinically significant complex for manual practitioners, surgeons, therapists, and pain practitioners. While conceptualizing conjoined nerve roots is best done in coronal orientation, like in the schematics, coronal images are rarely available in MRI studies. Therefore relying on clues from axial and sagittal images is the best way to identify this anatomical anomaly.

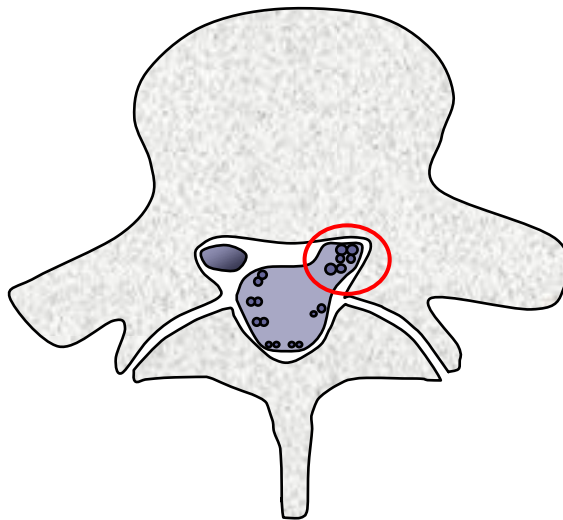


## Identifying Conjoined Nerve Roots on MRI

Asymmetry in the exiting nerve rootlets is an indication of possible conjoined nerve roots. The nerve rootlets should appear to travel in symmetrical pairs. The left and right side of the thecal sac should roughly mirror each other. Image 1 shows a group of several rootlets grouped together on the left side of the central canal (circled in red). Image 2 is a schematic of the axial image seen in image 1.



**Image 1:** T2W axial image showing asymmetry of the exiting nerve rootlets.

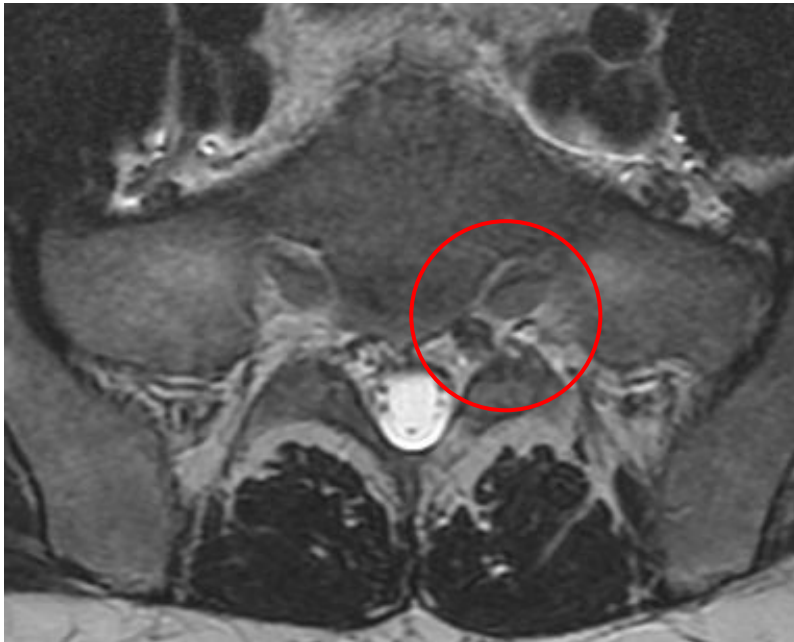

**Image 2:** Schematic of the axial slice seen in image 1.

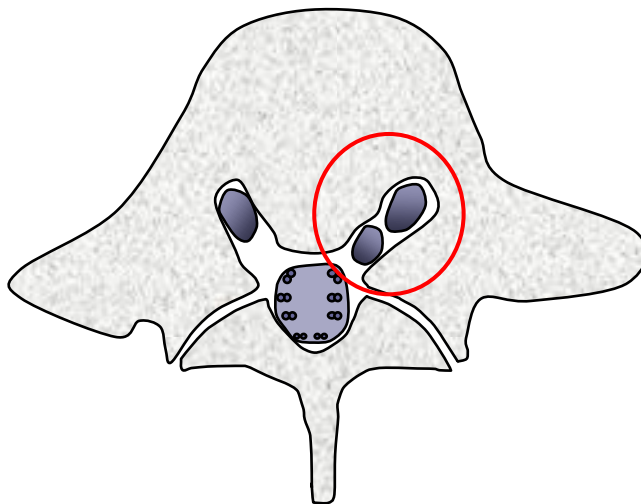


## Identifying Conjoined Nerve Roots on MRI

This T2W axial image reveals two nerves traveling in the same anterior sacral foramina. Nerves sharing the same foramina is an indicator of conjoined nerve roots.



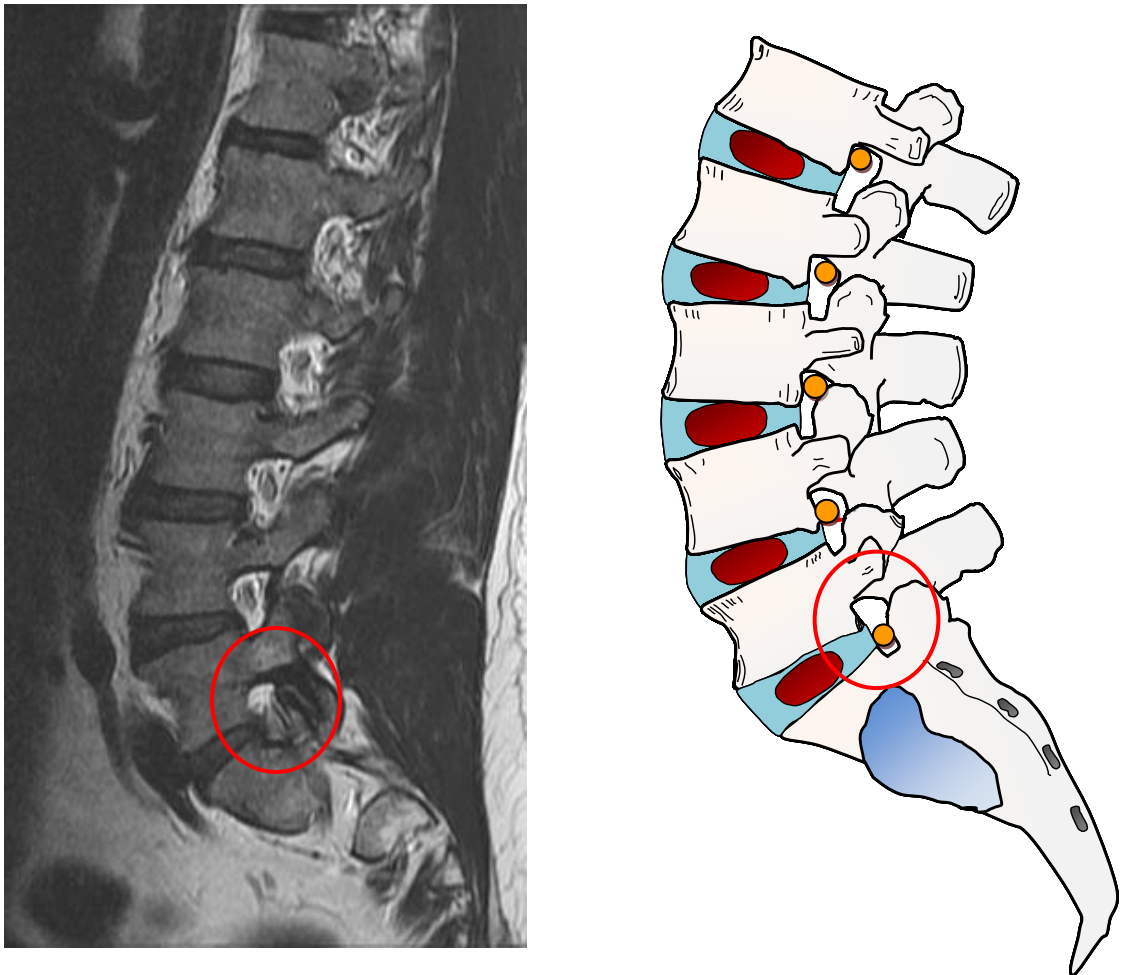
**Image 1:** T2W axial image showing two nerves sharing the same anterior sacral foramina (red circle).



**Image 2:** Schematic of the axial image of the sacrum shown in image

## Identifying Conjoined Nerve Roots on MRI

Nerve roots normally exit through the upper portion of the lumbar foramina. Suspect a conjoined nerve root if the nerve is located in the lower 1/3 of an IVF as seen in both the sagittal MRI on the left and the schematic on the right at L5-S1.



**Image 1:** T2W sagittal image and schematic showing an anchoring of the L5 nerve root in the lower portion of the L5-S1 foramina.

# Classification of Spinal Cord Tumors and Masses by Location

---

10

## Space Occupying Lesions, Tumors, and Masses

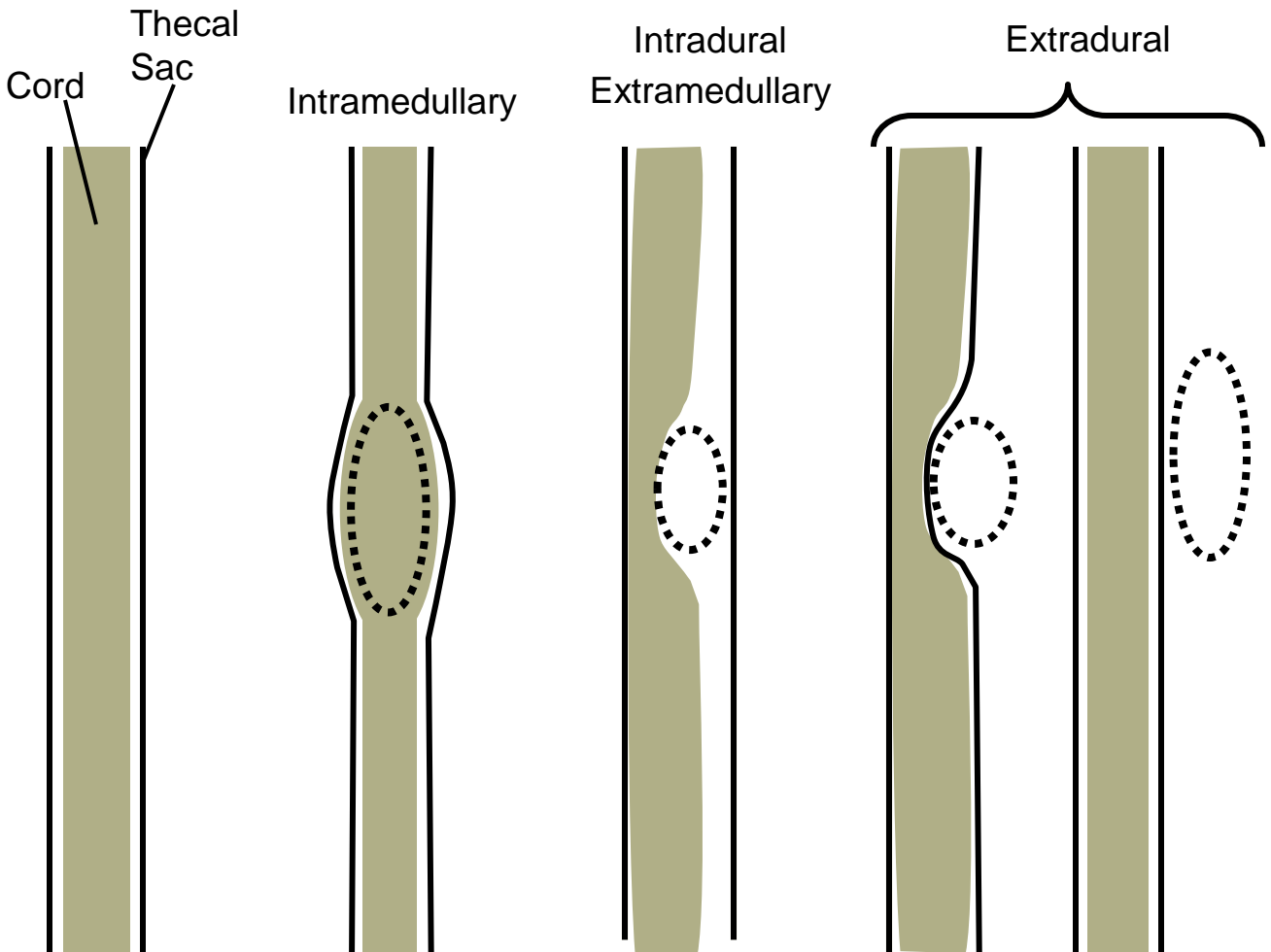
The identification, diagnosis, and classification of tumors and masses is best left to the experts: radiologists. Having said that, all MSK practitioners should have a basic understanding of the characteristics of space occupying lesions (SOL) and how they affect the surrounding structures.

The location descriptors in this chapter describe SOL location in relation to the spinal cord, cauda equina, and thecal sac. Spinal cord lesions fall into one of three categories: extradural, extramedullary, and intramedullary. Extradural lesions are spinal lesions that are found in the spine, but outside of the thecal sac. Intradural extramedullary lesions are found within the thecal sac, but outside of the spinal cord. Intramedullary lesions are found within the cord.

| Extradural Lesions  | Extramedullary Lesions   | Intramedullary Lesions   |
|---|--|--|
| <ul style="list-style-type: none"> <li>•Disc herniation</li> <li>•Metastasis to the vertebra</li> <li>•Synovial cyst</li> <li>•Hematomas</li> <li>•Abscess</li> <li>•Schwannoma*</li> <li>•Neurofibroma*</li> </ul> | <ul style="list-style-type: none"> <li>•Schwannoma*</li> <li>•Neurofibroma*</li> </ul> | <ul style="list-style-type: none"> <li>•Ependymoma</li> <li>•Astrocytoma</li> <li>•Hemangioblastoma</li> <li>•Syrinx</li> <li>•Demyelinating disease</li> <li>•Myelitis</li> </ul> |

\*Schwannomas and neurofibromas can be found intradurally and extramedullary. They are not intramedullary lesions.

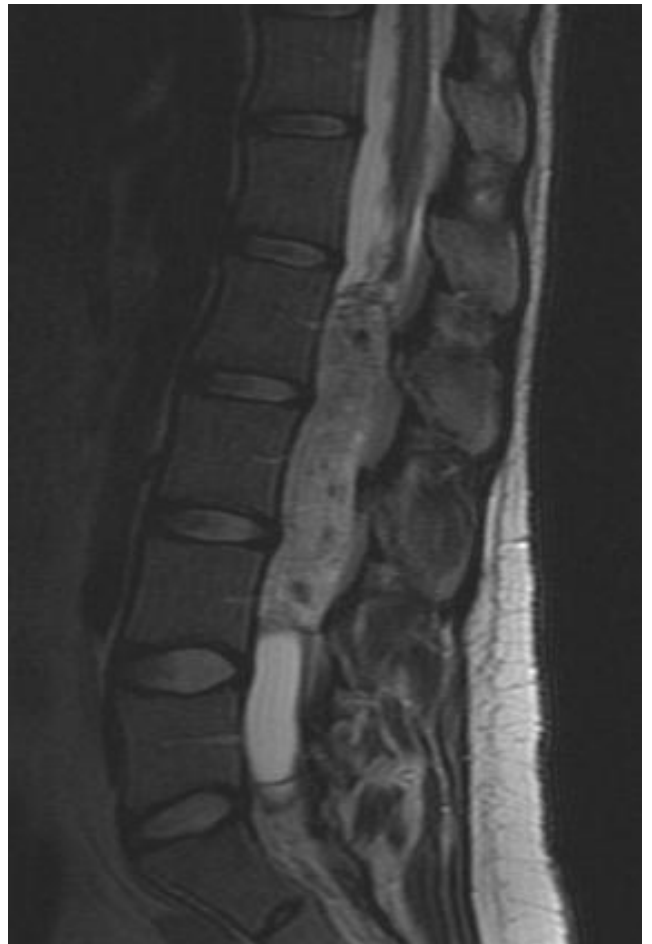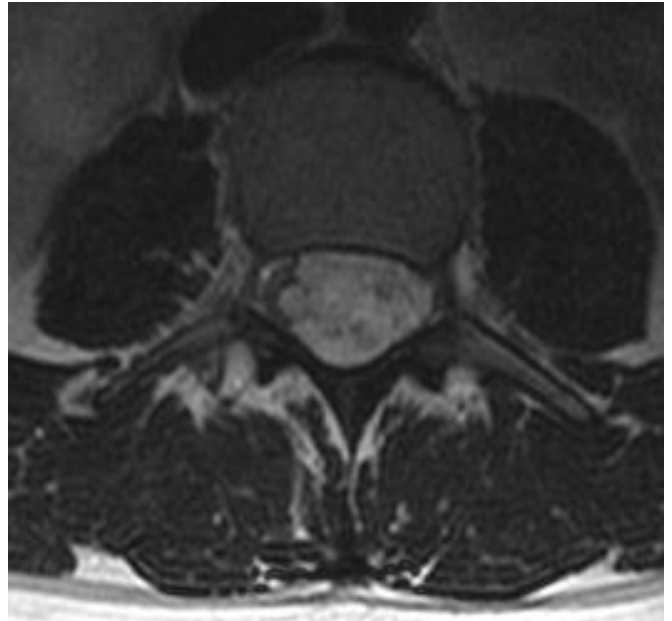

## Location Classification of Spinal Tumors and Masses



Space occupying lesions of the spine are categorized by their location and relationship to the thecal sac and to the spinal cord. Is the lesion within or outside of the cord? Is it inside or outside of the thecal sac? Is the lesion inside the thecal sac, but outside of the cord. These are the location identifiers for space occupying lesions of the spine. Lesions within the cord are called intramedullary lesions, cysts, or tumors. Lesions within the dura mata (the membrane of the thecal sac) are intradural lesions. Those located outside the dura mata are called extradural lesions, masses, cysts, or tumors. Since the cord terminates high in the lumbar spine, there will be few truly intermedullary lesions found in the lumbar spine. We can see expansive lesions in the conus medularis, the filum termanale, and even in the cauda equina.

## Intramedullary Tumors

### Intramedullary

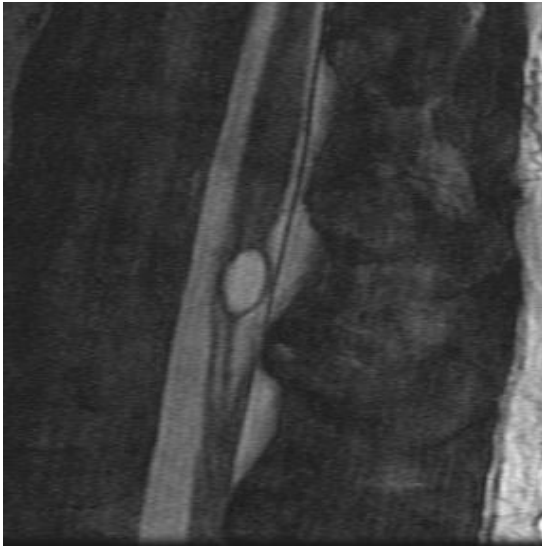

Ependymomas are an example of an intramedullary tumor. They are usually slow growing benign tumors arising from the epithelial lining of the spinal cord's central canal. These images show an expansive ependymoma within the filum terminale.

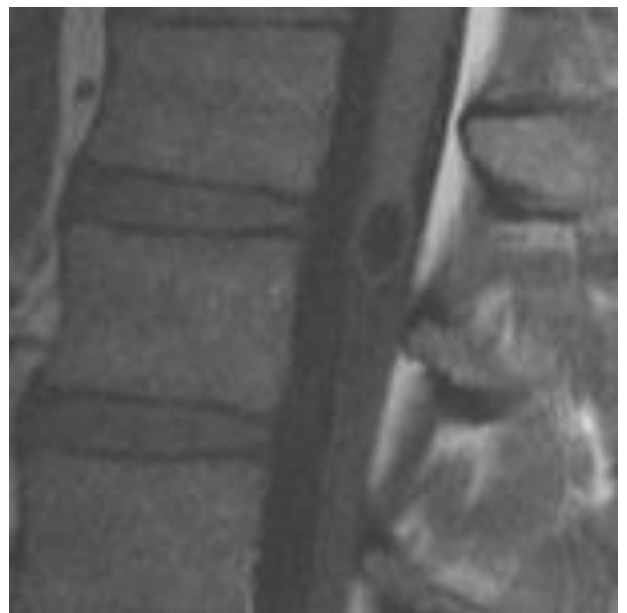
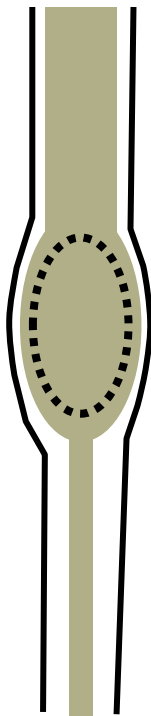
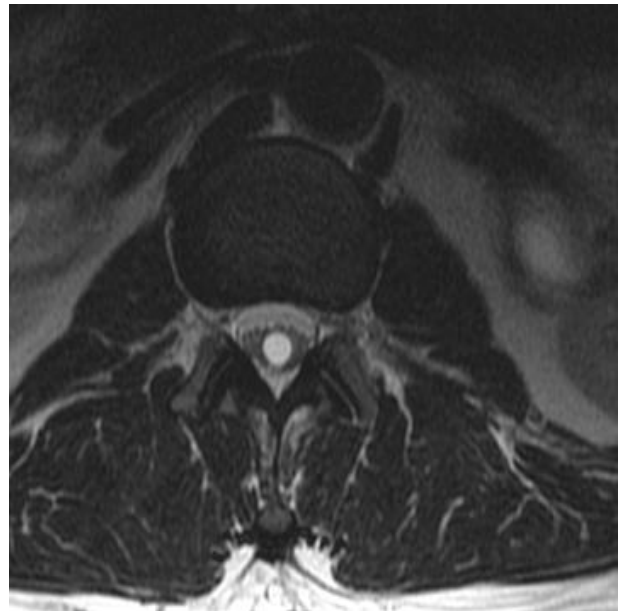
Ependymomas are the most common primary tumors of the spinal cord. As in this case they most frequently occur in the lower spinal cord or in the filum terminale.

1. Yuh EL, Barkovich AJ, Gupta N. Imaging of ependymomas: MRI and CT. *Childs Nerv Syst.* 2009 October; 25(10): 1203–1213

## Classification of Tumors and Masses

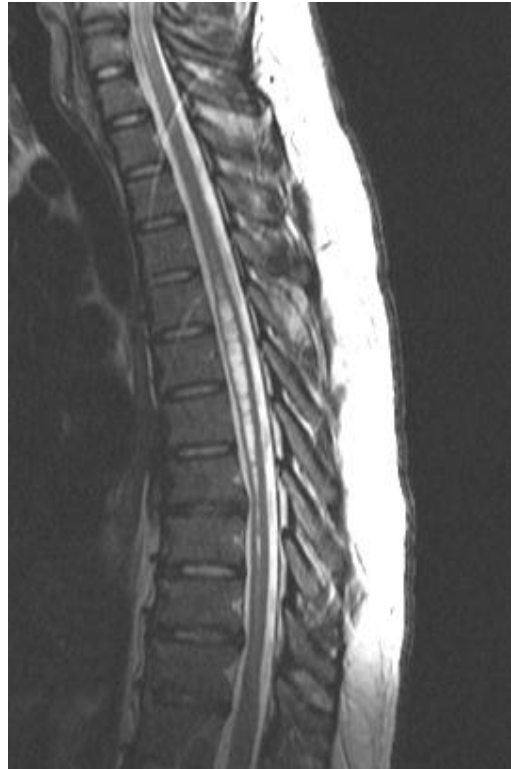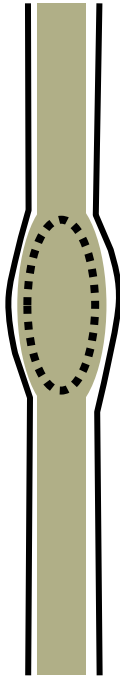


These images display a conus medullaris cyst. This lesion is considered an intramedullary cyst. The upper slices are FIESTA (Fast Imaging Employing Steady sTate Acquisition) images. The image below shows the cyst in T1 weighted imagery.

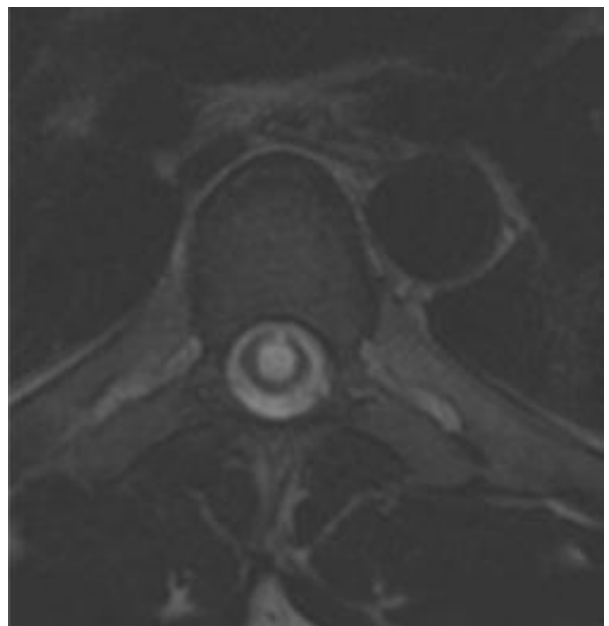


## Classification of Tumors and Masses

Intramedullary



These images display a syrinx involving the thoracic cord.

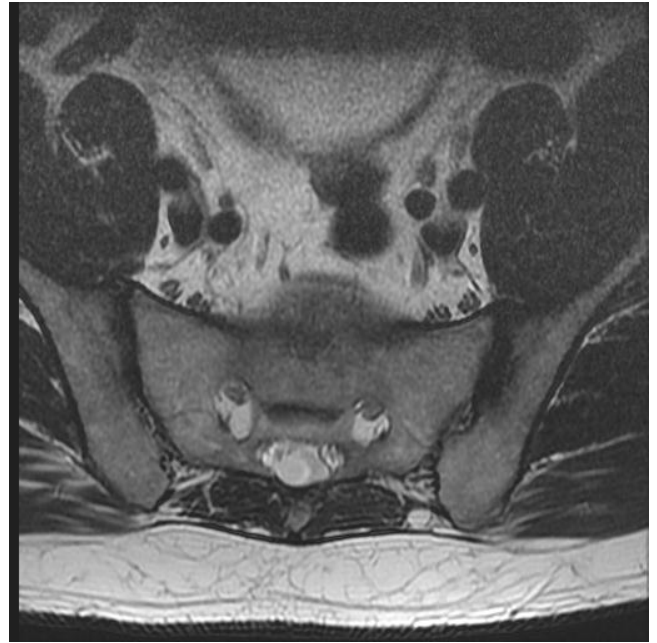


Syrinx in thoracic cord



## Classification of Tumors and Masses

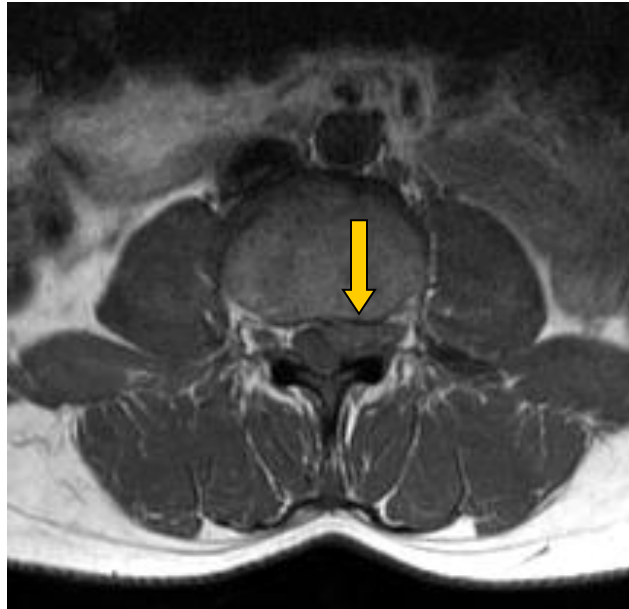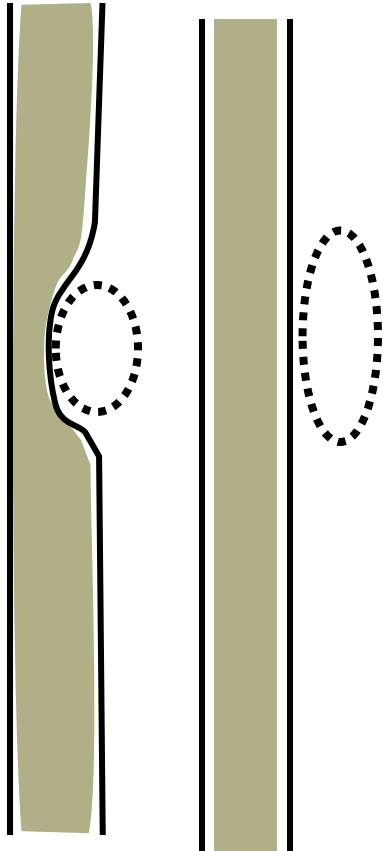
Intradural  
Extramedullary



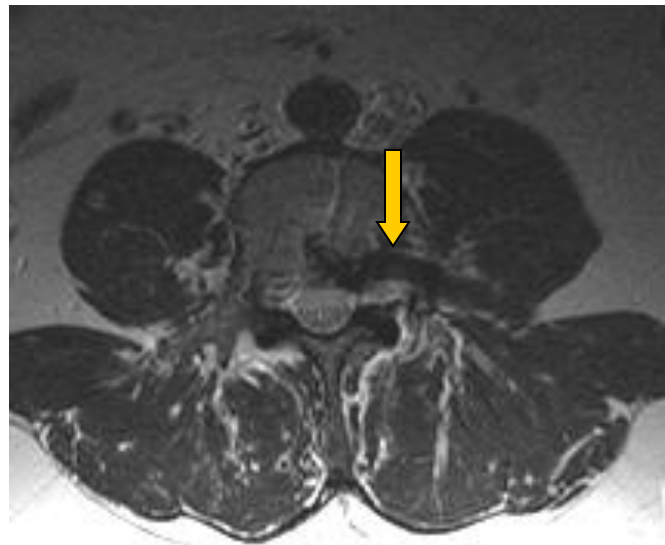
Fatty filum terminale

## Extradural Lesions

Extradural



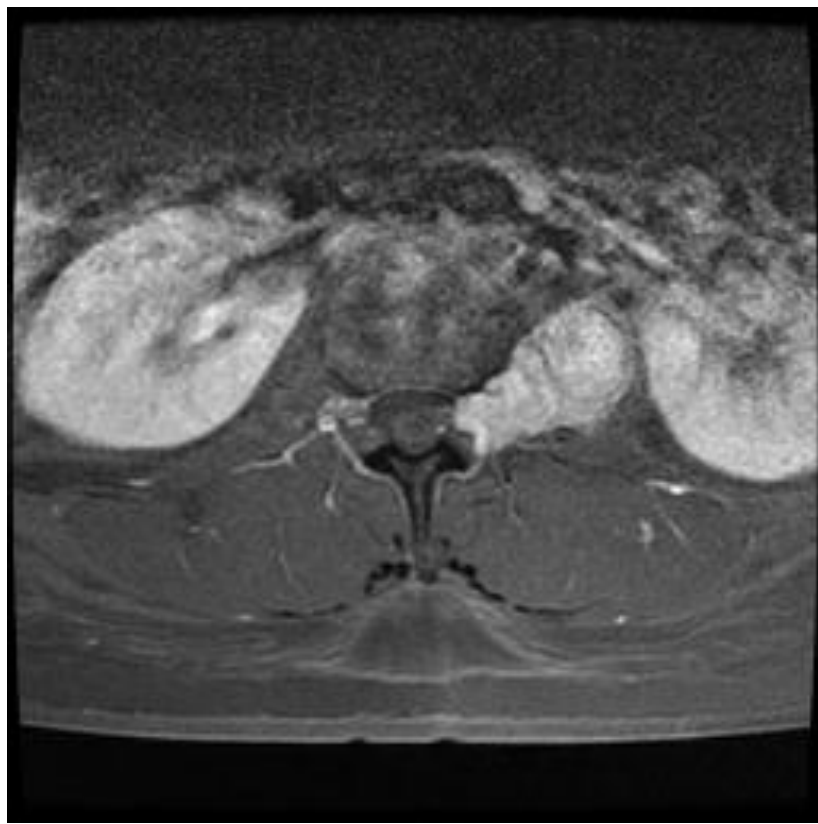
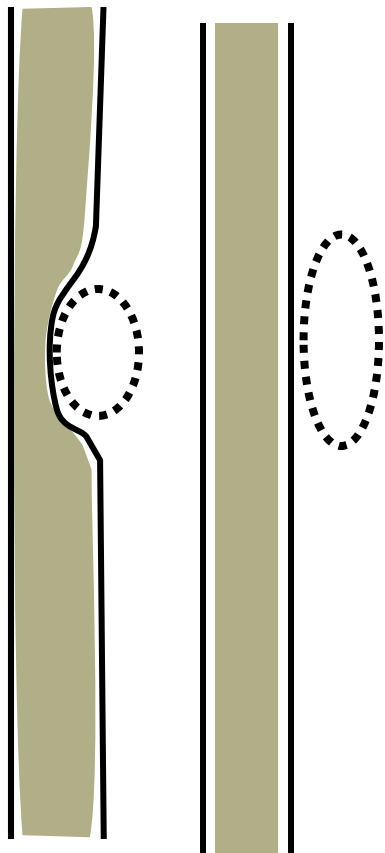
This image displays an extradural mass effacing the thecal sac.



This vascular anomaly of the intervertebral vein is an extradural lesion.

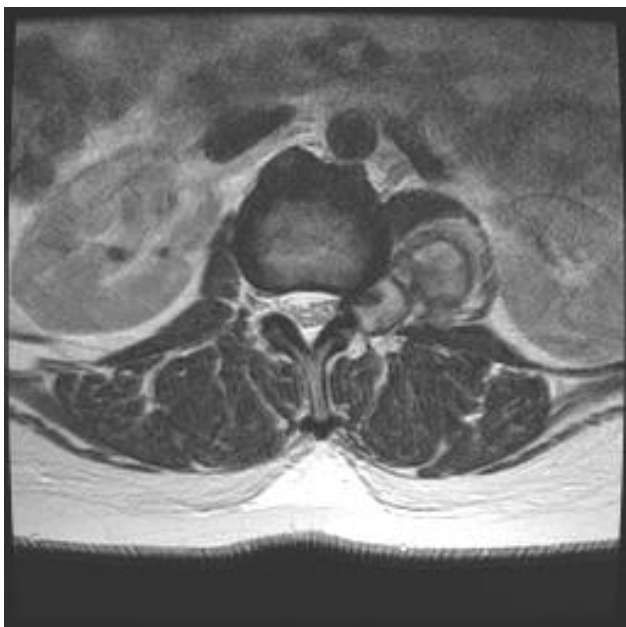## Extradural Lesions

Extradural

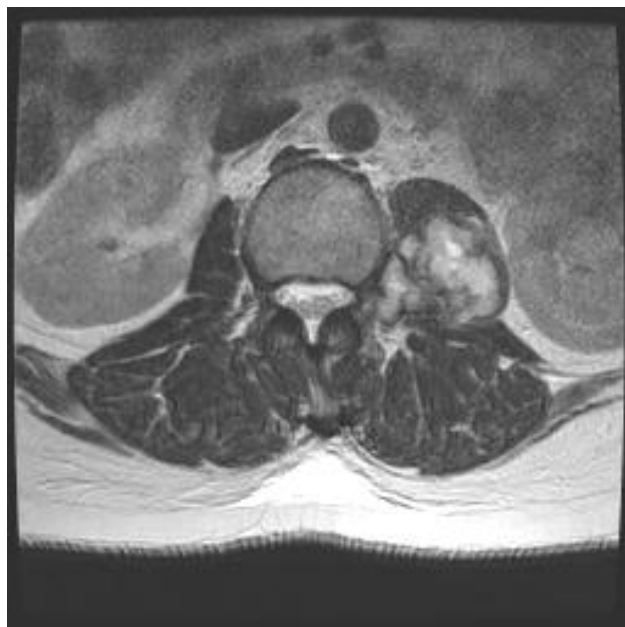


Schwannoma enhanced with gadolinium

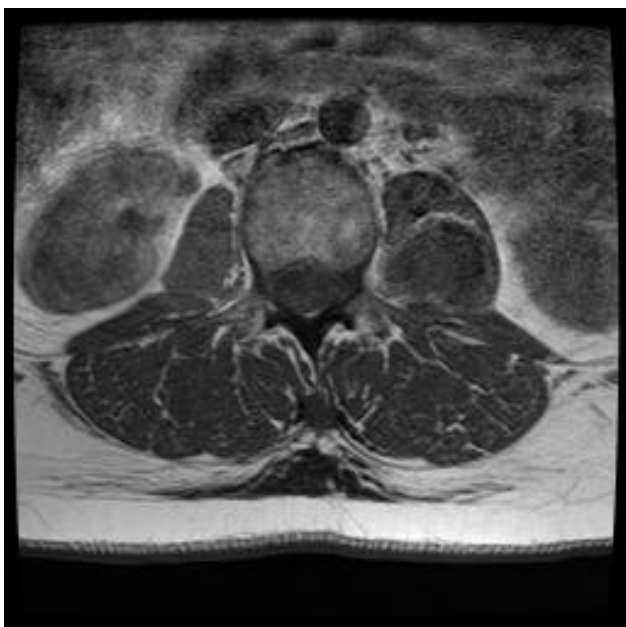## Schwannoma Extending through the IVF and into the Iliopsoas Muscle



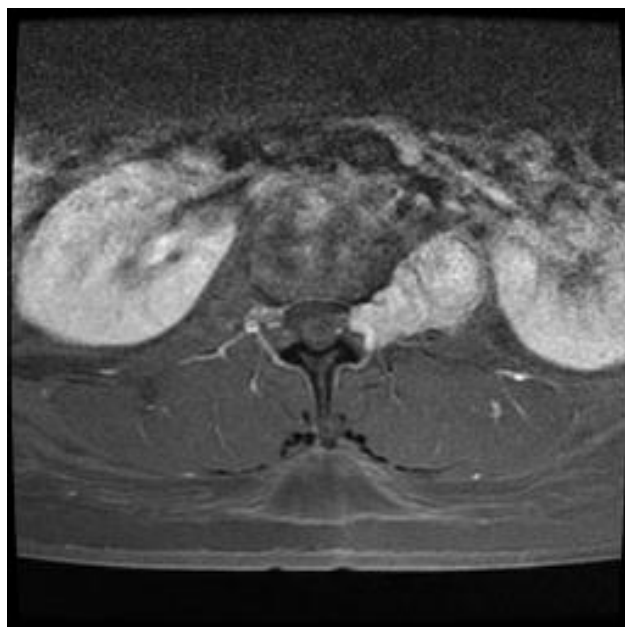**Image 1:** T2 weighted axial image showing heterogeneous expansion of a schwannoma into the left psoas.



**Image 2:** Another T2 weighted axial image showing heterogeneous expansion of a schwannoma into the left psoas.



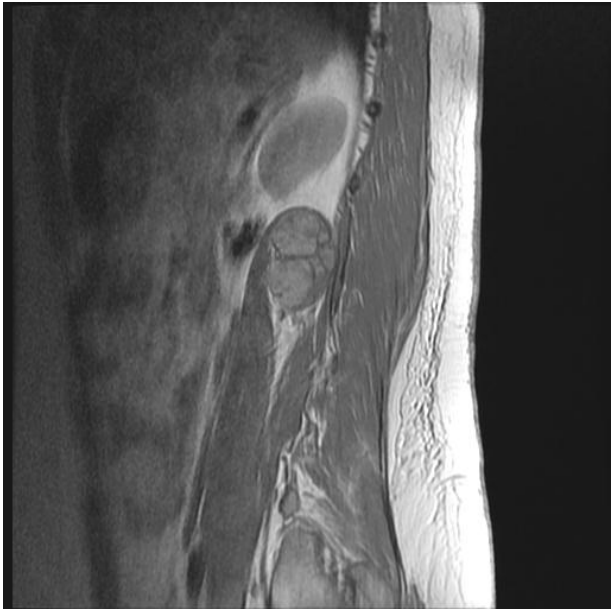**Image 3:** T1 weighted axial image. The Schwannoma is dark in color.



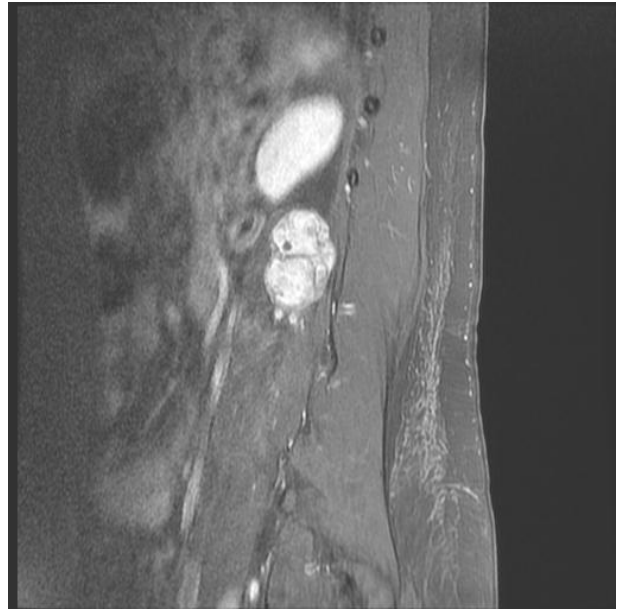**Image 4:** T1 weighted axial image with gadolinium enhancement. The fat is suppressed, but the kidneys and the schwannoma shine bright.

Sagittal images of this schwannoma continued on next page.

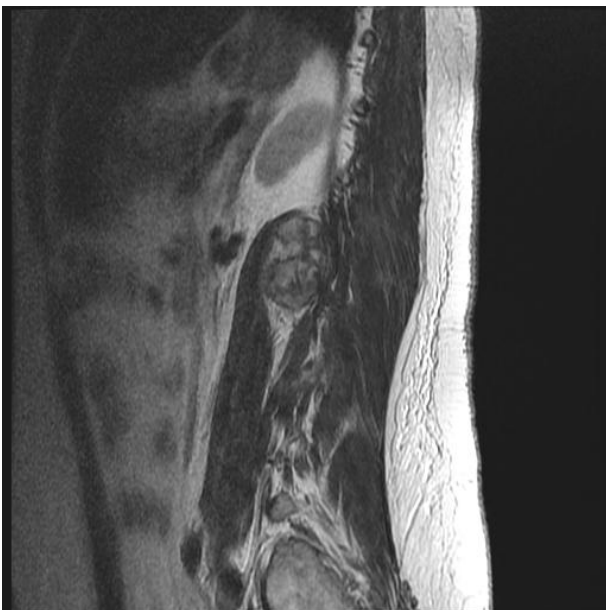## Schwannoma Protruding Through the Iliopsoas Muscle



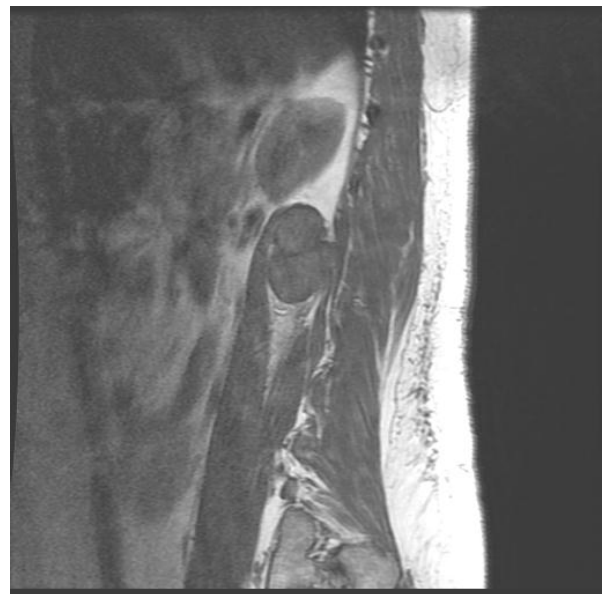**Images 1:** Proton density sagittal image of a schwannoma protruding through the iliopsoas muscle.



**Images 2:** Post-gadolinium T1 weighted sagittal image of a schwannoma protruding through the iliopsoas muscle. Note the high intensity of the tumor and the kidney.



**Images 3:** T2 weighted sagittal image of a schwannoma.



**Images 4:** T1 weighted sagittal image of a schwannoma.

# Perineural (Tarlovs) Cysts

---

11

# Perineural (Tarlovs) Cysts

Perineural cysts (aka Tarlov cysts, Tarlovs cysts, and Tarlov's cysts) are fluid-filled meningeal dilations of the posterior nerve root sheath, usually at the dorsal root ganglion. They are commonly viewed in the sacrum<sup>1</sup> but can also be observed in the lumbar, thoracic, and cervical spine. Dr. Isadore Tarlov first described the presence of perineural cysts in 1931 while studying the histology of the filum terminale at Royal Victoria Hospital in Montreal. Since then, this finding has borne his name. Despite its identification 70 years ago, scant scientific knowledge is available about this condition. Studies have shown perineural cysts to be present in 4.6-9% of the population.<sup>2</sup> Although they are usually considered a coincidental finding on MRI and predominantly asymptomatic, perineural cysts have been found to be symptomatic up to 20% of the time<sup>3</sup> and could pose a challenge to both the patient and the clinician.

## Radiography

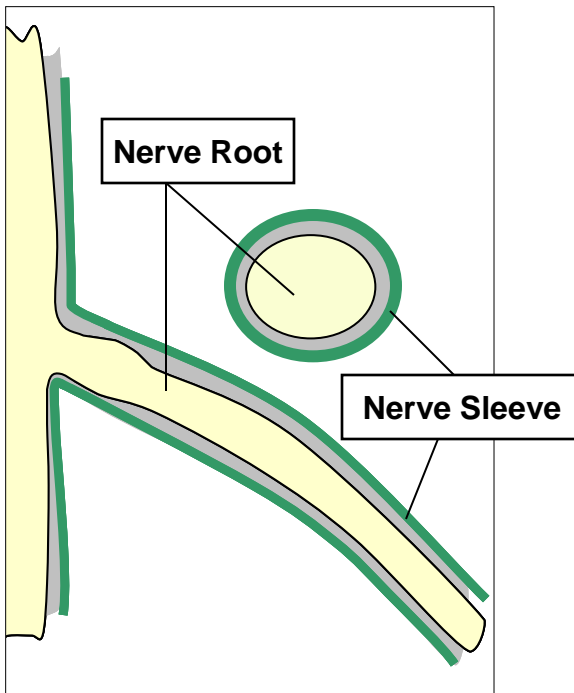
The advent of advanced diagnostic imagery such as MRI and CT, has resulted in more frequent reports of perineural cysts. It is rare for any diagnostic imaging procedure to be ordered for the sake of identifying a perineural cyst. Perineural cysts are commonly found on MRIs taken for other diagnostic purposes.

On MRI, perineural cysts are typically seen as well-circumscribed and ovoid in shape. They tend to exist as singularities and less often in clusters. T2 weighted MRI is the preferred medium to view perineural cysts. In T2 weighted MRI, water density appears white; in T1 weighted MRI, water density structures appear black and may be more difficult for the less experienced eye to visualize. Perineural cysts can also be made visible with computer tomography (CT), particularly when intrathecal contrast enhancement is used. CT with enhancement is used to determine the degree of communication between the perineural cysts and the thecal sac. Bony erosion caused by perineural cysts can be identified on plain film radiographs, but this is not the preferred medium for viewing this phenomenon.

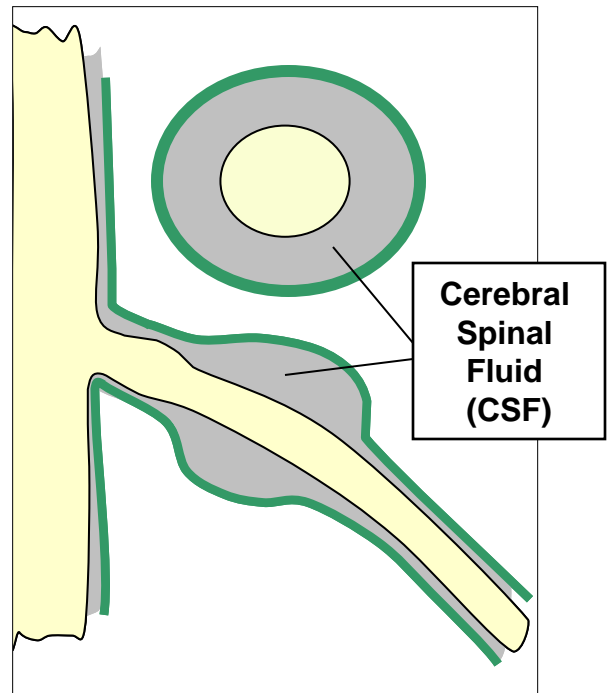
## References

1. Seaman WB, Furlow LT. The myelographic appearance of sacral cysts. *J Neurosurg* 1956;13:88-94.
2. Paulsen RD, et al. Prevalence and percutaneous drainage of cysts of the sacral nerve root sheath (Tarlov cysts). *AJNR* 1994; 15:293,297.
3. Mummaneni PV, et al. Microsurgical treatment of symptomatic sacral Tarlov cysts. *Neurosurgery* 2000; 47:74-79.
4. Bartels RH, van Overbeeke JJ. Lumbar cerebrospinal fluid drainage for symptomatic sacral nerve root cysts: an adjuvant diagnostic procedure and/or alternative treatment? Technical case report. *Neurosurgery* 1997; 40:861-865.
5. Patel MR, et al. Percutaneous fibrin glue therapy of meningeal cysts of the sacral spine. *AJR* 1997; 168:367-370.
6. Voyadzis JM, e. Tarlov cysts: a study of 10 cases with review of the literature. *J Neurosurg (Spine 1)* 2001;95:25-32.

## What is a Perineural (Tarlovs) Cyst?

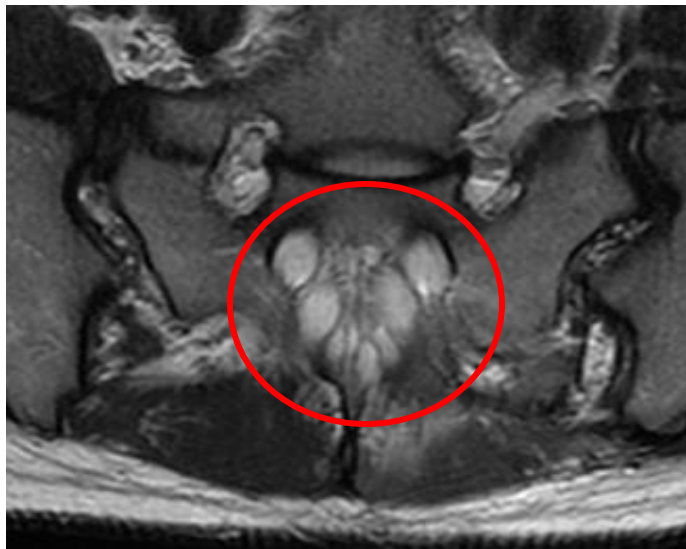

**Schematic of the normal nerve root**



**Dilation of the Nerve Sleeve and Filling with CSF**

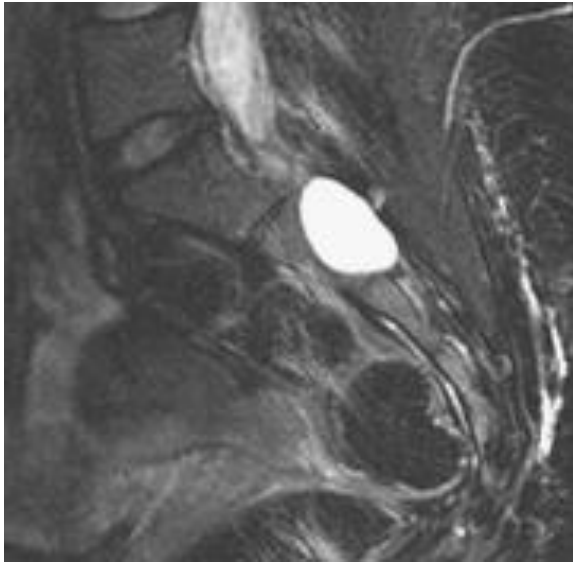
Perineural cysts are fluid-filled meningeal dilations of the posterior nerve root sheath, usually at the dorsal root ganglion. These schematics illustrate the normal relationship of the dural sleeve and the nerves. The T1 image of the sacrum shows eight perineural cysts clustered together like a cluster of grapes.



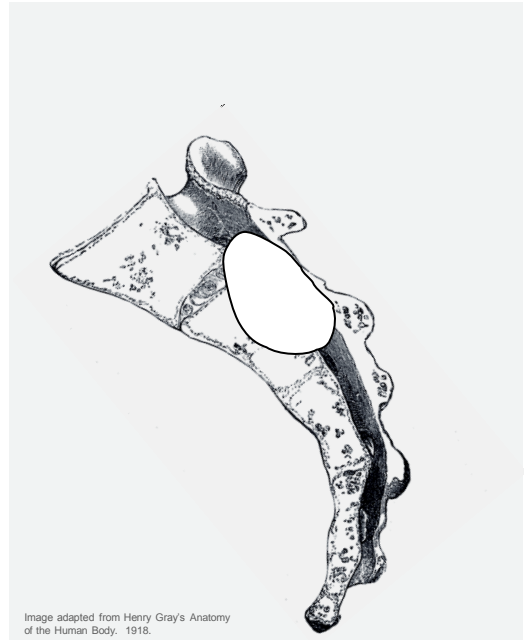


## Characteristics of Perineural Cysts on MRI

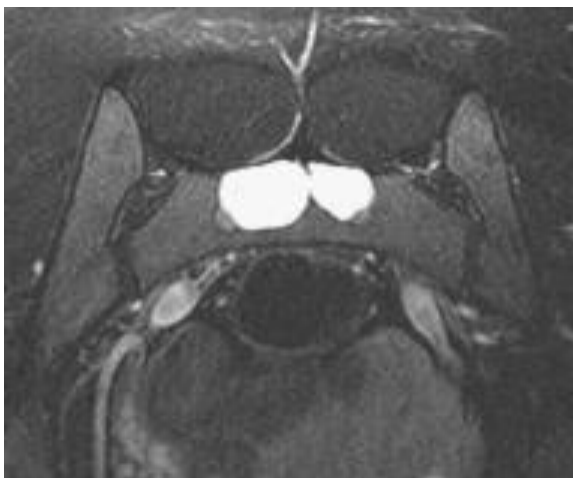This sequence of images demonstrates the characteristics of two large perineural cysts affecting the dural sleeves of the S2 nerve roots. Note the high intensity of the perineural dilation of the cysts in T2 and the low intensity of the cysts on T1. These images also reveal significant bony erosion of the sacrum which weakens the integrity of the sacrum.



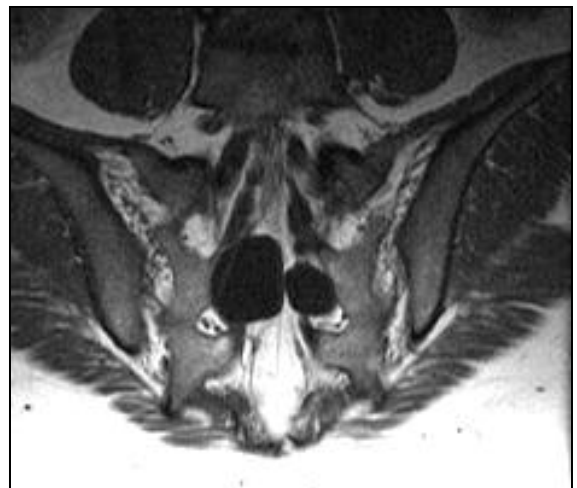
**Image 1.** Large ovoid perineural cysts affecting the sleeve of the S2 nerve root on fat suppressed T2 weighted image.



**Image 2.** Schematic of the cyst



**Image 3.** Axial fat suppressed T2 weighted image demonstrating two large perineural cysts in the sacrum.



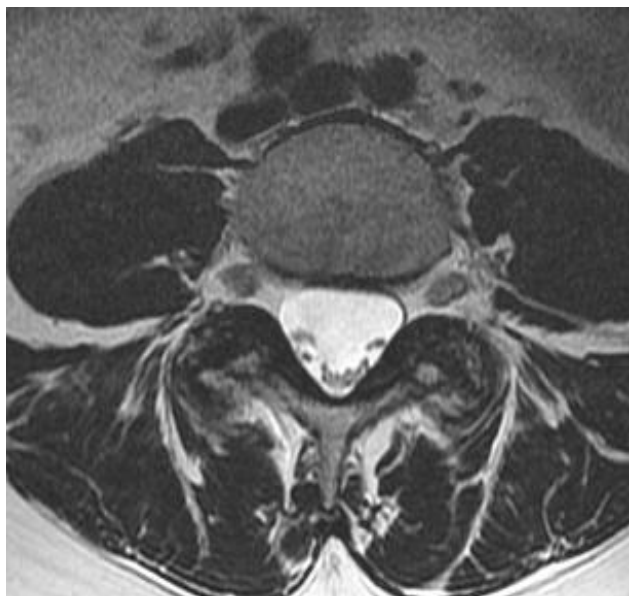
**Image 4.** T1 image of perineural cysts. Fat is hyper-intense, while the perineural cysts are hypo-intense (black).

# Stenosis

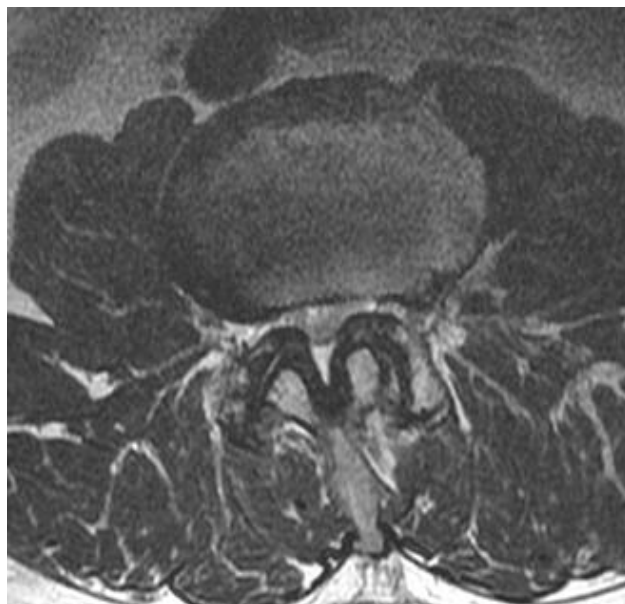---

12

## Central Canal Stenosis



**Image 1.** Normal lumbar central canal. This T2 weighted axial image clearly shows a patent central canal.

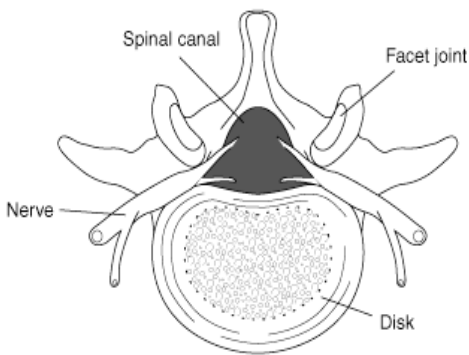


**Image 2.** Lumbar stenosis of the central canal and lateral recesses secondary to facet hypertrophy and ligamentum flavum hypertrophy.

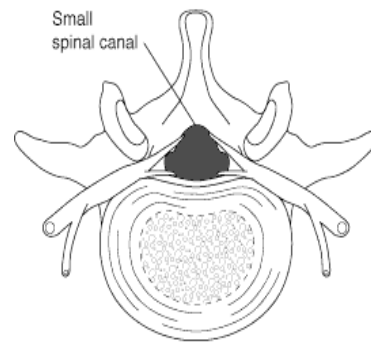
Spondylosis may result in degenerative stenosis. The combination of decreased disc height, enfolding and thickening of spinal ligaments, and bony hypertrophy contribute to this slowly progressing condition. The image on the left (image 1) shows a widely patent central canal, lateral recesses (subarticular zone), and intervertebral foramina. The exiting nerve roots are suspended in a supple cradle of fat.

The image on the right (image 2) reveals a moderately severe stenosis that affects the central canal, lateral recesses, and foramina. The point at which a narrowing of the canal becomes a stenosis is imprecise and is usually left to the interpretation of the radiologist.

## Congenitally Narrowed Central Canal



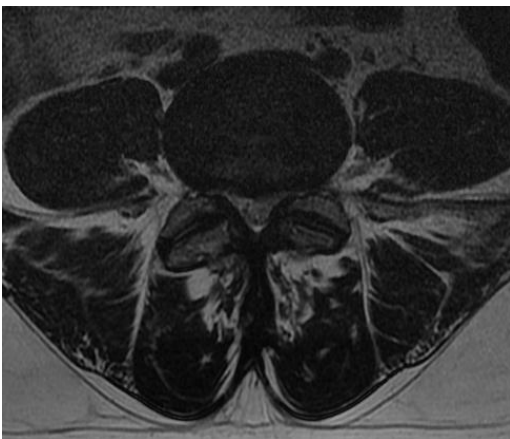
**Image 1.** Normal lumbar central canal



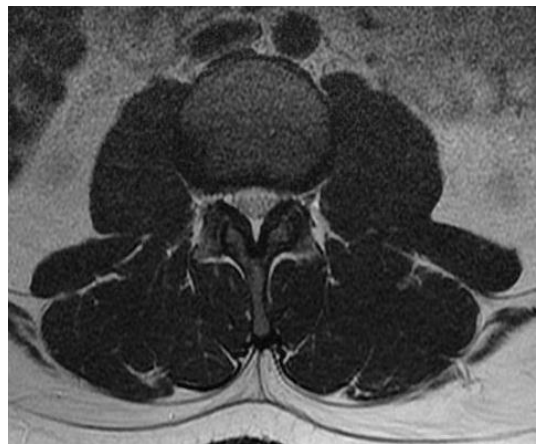**Image 2.** A congenitally small canal

A developmentally narrowed central canal tends to produce stenosis symptoms earlier and with a more profound clinical presentation than a more patent canal. A congenital canal tends to have a more rapid onset of stenosis with less spinal degeneration. The difference between a congenitally narrowed canal and a stenosis is that a stenosis refers to a focal narrowing of the canal, whereas a congenitally narrowed canal is the generalized narrowing of the canal. Shortened pedicles are frequently blamed for congenital narrowing of the canal.

Clinically, patients with congenital stenosis will report with multiple levels of stenosis, and they present with symptoms at a younger age.



**Image 3.** A congenitally narrowed central canal in a 32 year-old female. Her stenosis is compounded by space occupying hypertrophy of the facets.

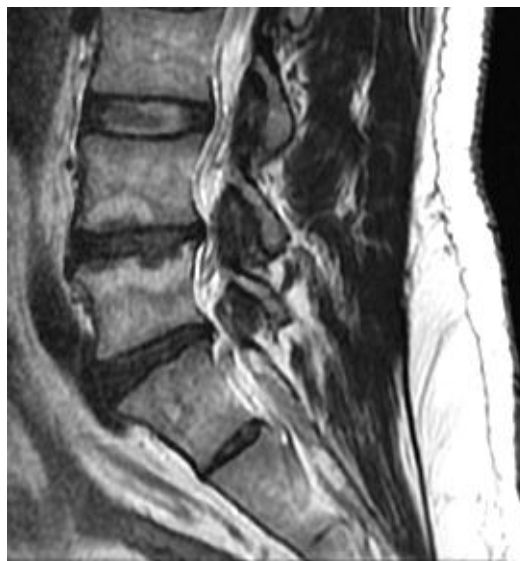
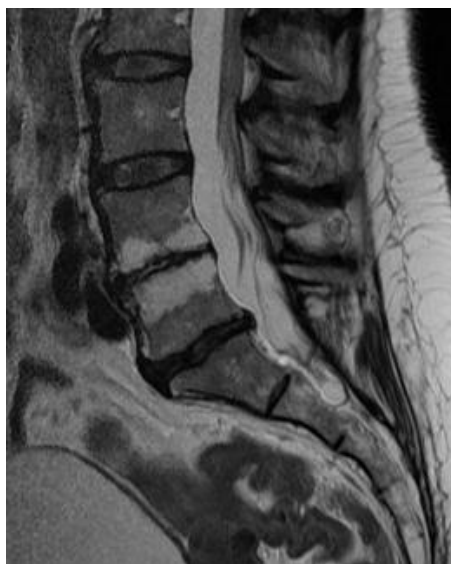
**Image 4.** A congenitally narrowed central canal in a 23 year-old male.

Clark K. Significance of the small lumbar spinal canal: cauda equina compression syndromes due to spondylosis. 2. Clinical and surgical significance. J Neurosurg 1969 Nov;31 (5):495-8.

# Modic Changes on MRI: Vertebral Body Marrow Morphology

## Modic Changes



Vertebral body edema is a common finding on MR imagery, but it is frequently left absent from radiographic reports. This may be due to the radiologist considering this finding clinically irrelevant, or the more practical consideration that every finding on MR cannot be recorded and most practitioners do not want excessive details. Most practitioners want to know if there is a need for surgical referral or a referral to an oncologist: “Is there neurological defect? Is there a neoplasm?” Degenerative changes like bony edema may seem like unimportant background noise to the busy clinician. However, recent studies have found that that vertebral marrow edema is clinically significant and can be progressive.

Michael T. Modic, MD identified and published his findings on vertebra bony marrow changes in the journal *Radiology* in 1988. Since that time these findings and his grading criteria has born his name. Modic changes represent MR observations of vertebral marrow and endplate changes. These changes have been linked to trauma, disc disruption, and degeneration. More studies are currently underway to identify the clinical significance of this finding and to fully understand its progression.

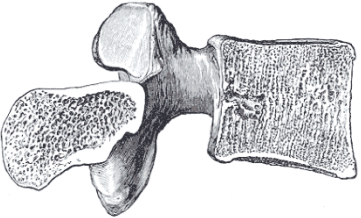
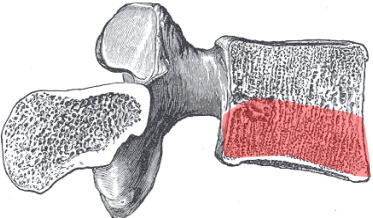
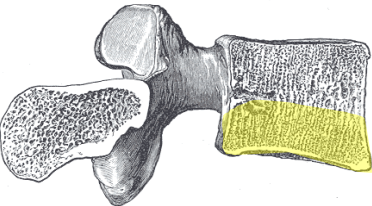
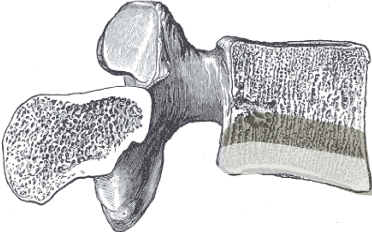
The vertebral body has a dense outer barrier of cortical bone that is particularly dense at the vertebral endplates. Within this tough outer shell lies the subcortical marrow cavity. This cancellous bone is less dense and is porous. It is normal for this porous bone to contain fatty marrow. The T1 and T2 weighted images will reflect the presence of normal fatty marrow with a supportive bony matrix. When edema is present in the marrow, it is characterized by an influx of water content: T1-weighted images show loss of signal (hypointense signal in the marrow), while T2-weighted images will demonstrate an increased (hyperintense) signal.

Modic MT, Steinberg PM, Ross JS, et al. Degenerative disc disease: Assessment of changes in vertebral body marrow with MR imaging. *Radiology*, 1988;166:193-9.

Modic MT, Ross JS. Lumbar degenerative disk disease. *Radiology*. 2007 Oct;245 (1): 43-61

## Bone Morphology and Modic Classifications

Evidence is emerging that indicates that there is a progressive nature to Modic changes. The bony edema of type I Modic changes may progress to type II, and type II may progress to type III.

| Characteristics of Bone Morphology in Vertebral Bodies   |   |
|--|---|
| <p>Normal bone is spongy and uniform in appearance. The vertebral endplates are a thin dense margin of bone.</p>   |  <p style="text-align: center;"><b>Normal</b></p>                 |
| <p>Bony edema has been connected with acute endplate or disc disruption. This edema is visible on MRI and is classified as Type 1 Modic change. It has been associated with pain and inflammation.</p>   |  <p style="text-align: center;"><b>Type 1 Modic Changes</b></p>  |
| <p>Type 2 Modic changes are indicative of yellow fatty infiltration into cortical bone following bony ischemia. Type 2 Modic changes may progress from type 1 Modic changes.</p>   |  <p style="text-align: center;"><b>Type 2 Modic Changes</b></p> |
| <p>Type 3 changes are categorized by sclerotic changes of subchondral bone and thickening of the endplates. In time, thickened endplates will reduce nutrient and fluid movement into adjoining discs. This will contribute to reduced fluid content within the adjoining disc and subsequent degenerative disc disease.</p> |  <p style="text-align: center;"><b>Type 3 Modic Changes</b></p> |

Images adapted from Henry Gray (1821–1865). *Anatomy of the Human Body*. 1918.

## Type 1 Modic Characteristics

**Bony edema extending into the spongy subcortical bone.**

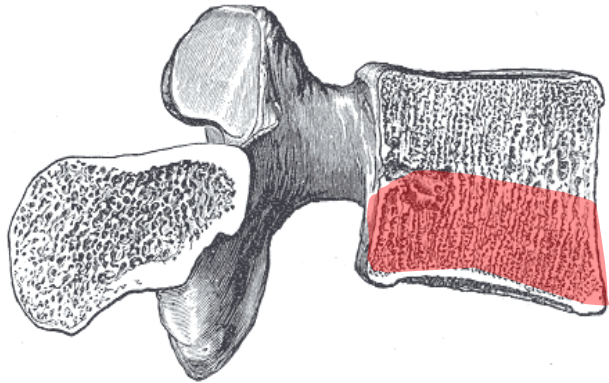
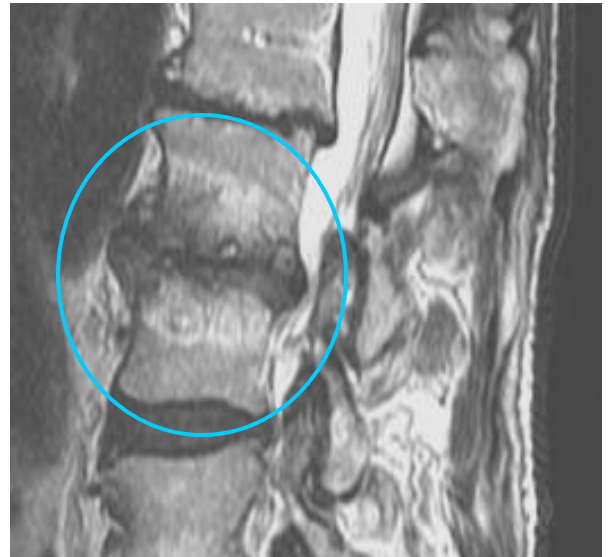
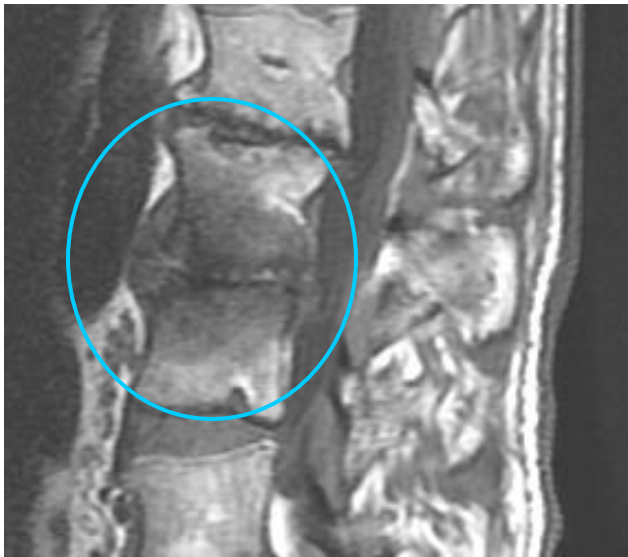

Image adapted from Henry Gray (1821–1865). *Anatomy of the Human Body*. 1918.

The high water content of inflammation and edema. Type 1 changes are manifested as hypointense (dark) on T1 and hyperintense on T2 weighted images.



**T1 weighted image**

**T2 weighted image**



## Type 2 Modic Characteristics

### Fatty infiltration

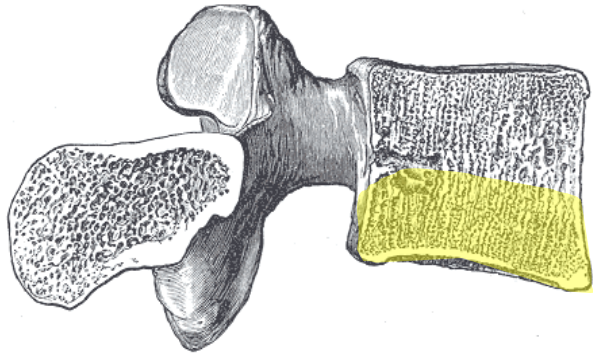
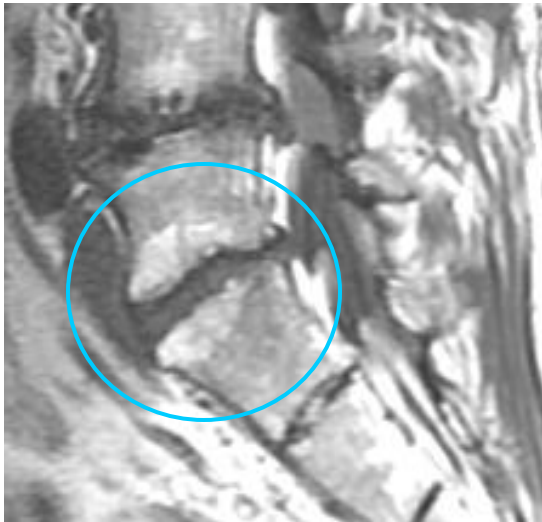
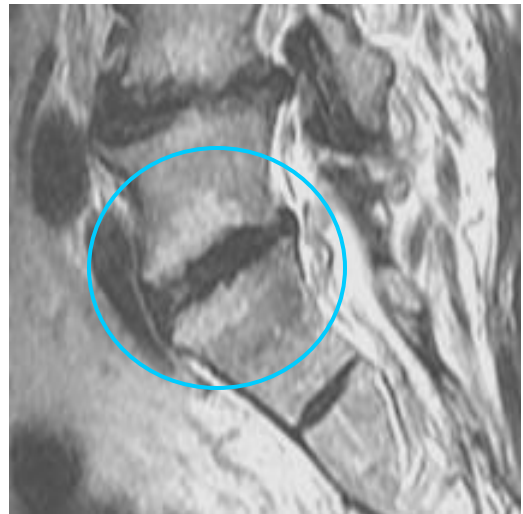
Image adapted from Henry Gray (1821–1865). *Anatomy of the Human Body*. 1918.

On T1 images, the fatty infiltration of Type 2 Modic changes will appear hyperintense, and on T2 weighted images, they will appear hyperintense or isointense.



**T1 weighted image**



**T2 weighted image**

## Type 3 Modic Characteristics

**Sclerotic changes of the cortical bone and thickening of the vertebral endplates.**

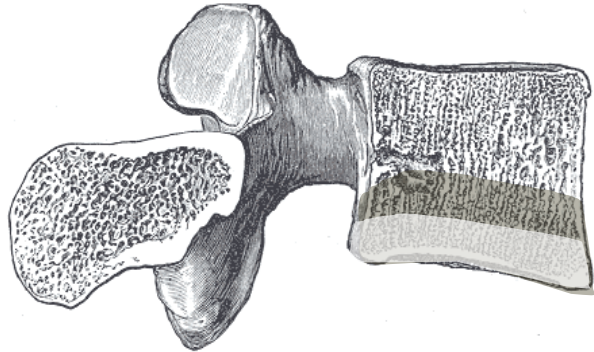
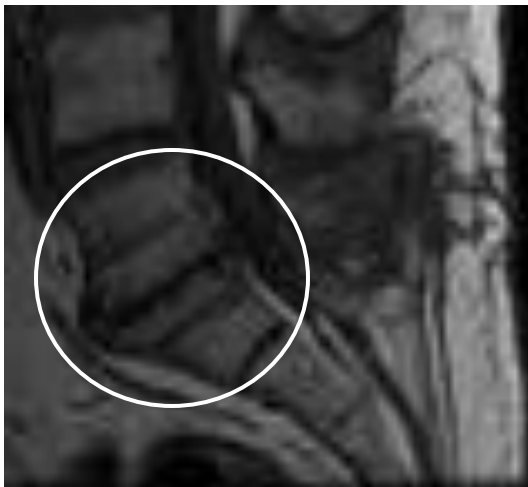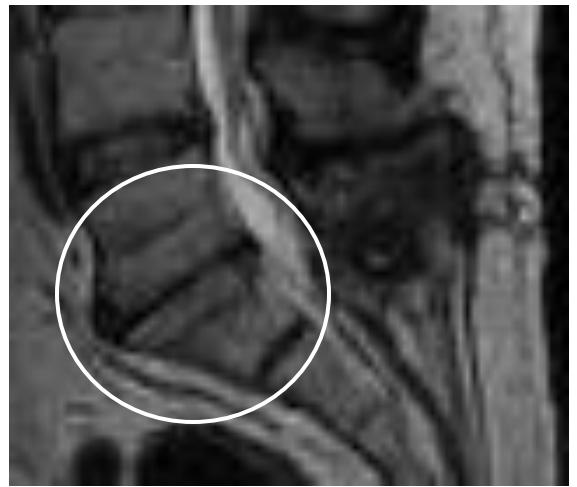


Image adapted from Henry Gray (1821–1865). *Anatomy of the Human Body*. 1918.

T1 and T2 weighted MRI will manifest type 3 Modic changes with decreased signal or hypointense. These findings can typically be correlated with sclerosis on plain film x-ray. The images below demonstrate type 3 Modic changes in a patient with degenerative disc disease of L5-S1 following an old discectomy.



**T1 weighted image**



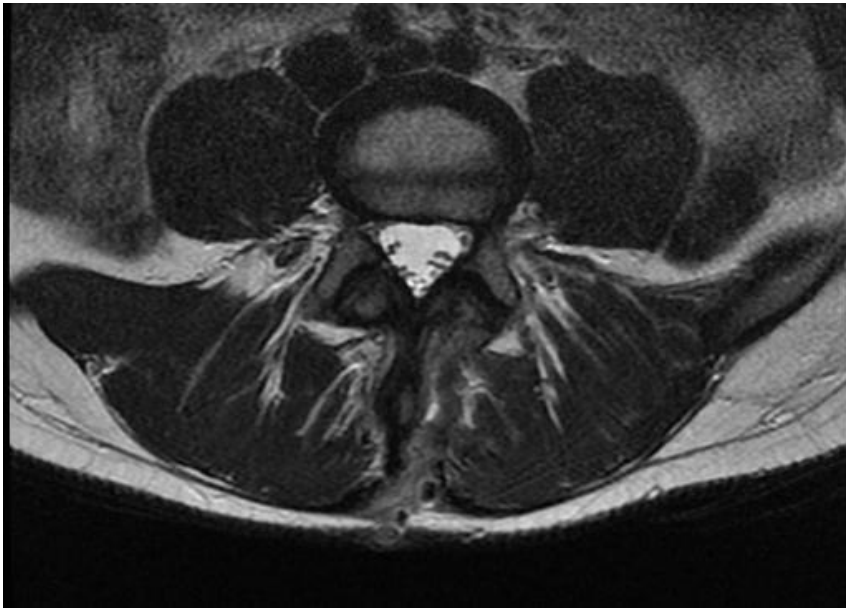
**T2 weighted image**

# Post-Surgical Findings

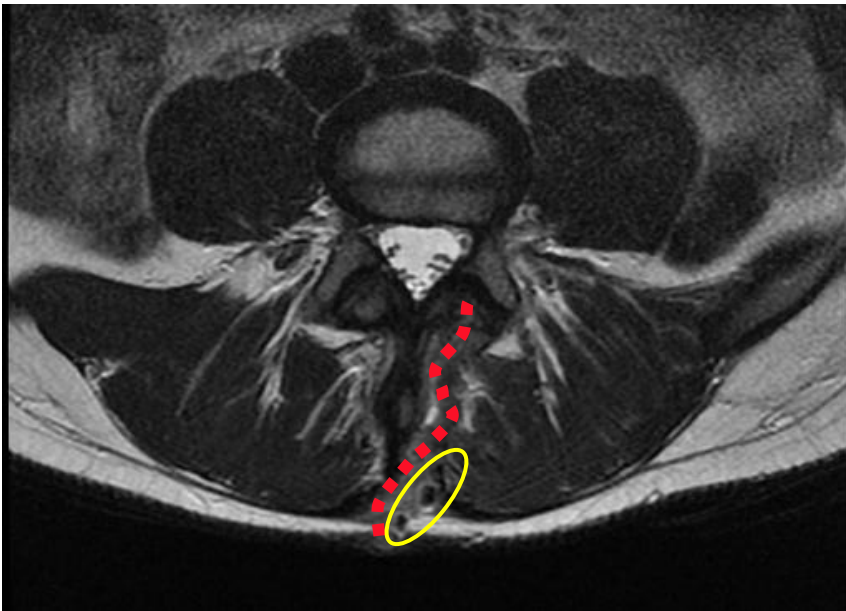
---

14

## Hemilaminectomy

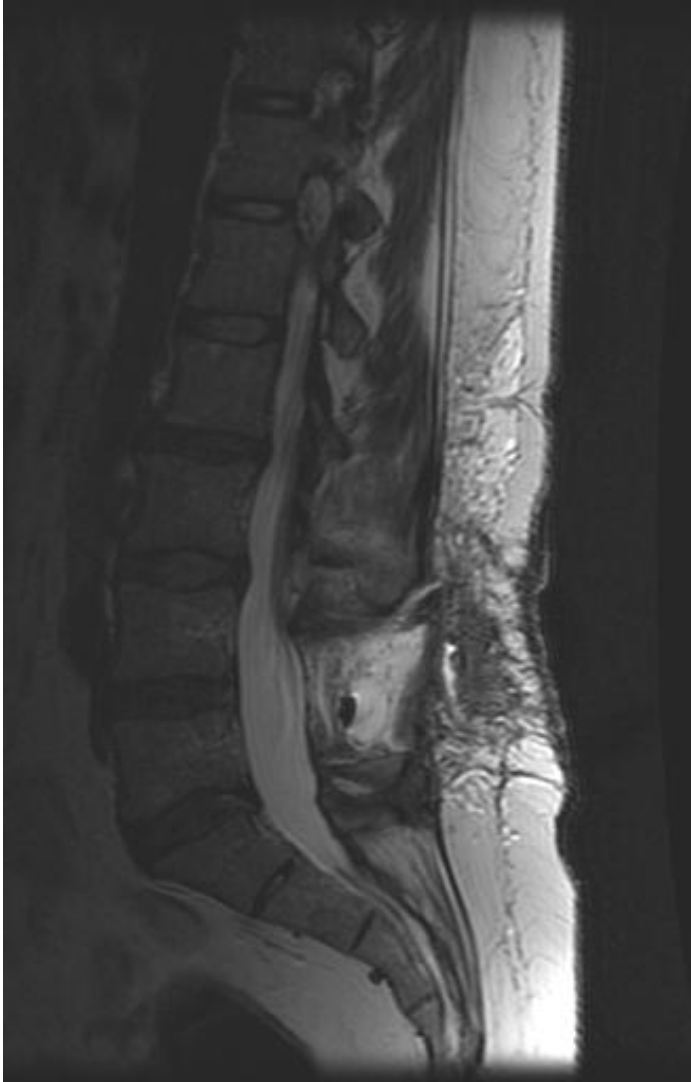

**Image 1.** This T2W axial image shows the healing scar of a hemilaminectomy

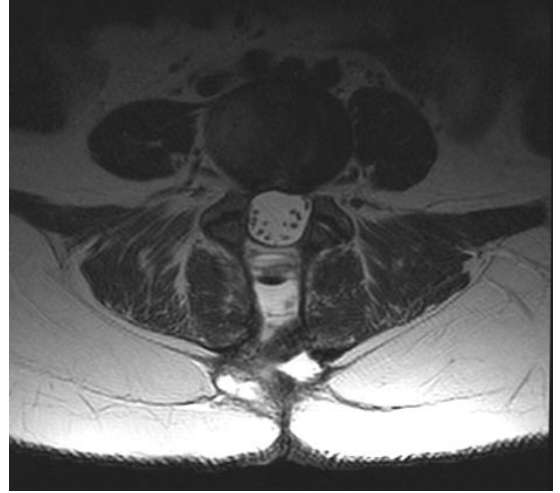

**Image 2.** This image is the same slice as image 1 with the surgical path shown with a red dashed line. The yellow oval shape contains three cystic lesions along the surgical path.

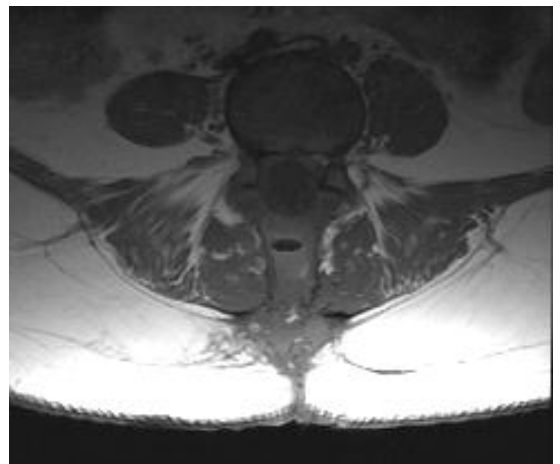
## Laminectomy



**Image 1.** This is a T2W sagittal image of an L5 laminectomy. Note the path of the surgeon through the subcutaneous fat, the absence of the L5 lamina and spinous process, and the air pocket in the void where the L5 spinous process had been.



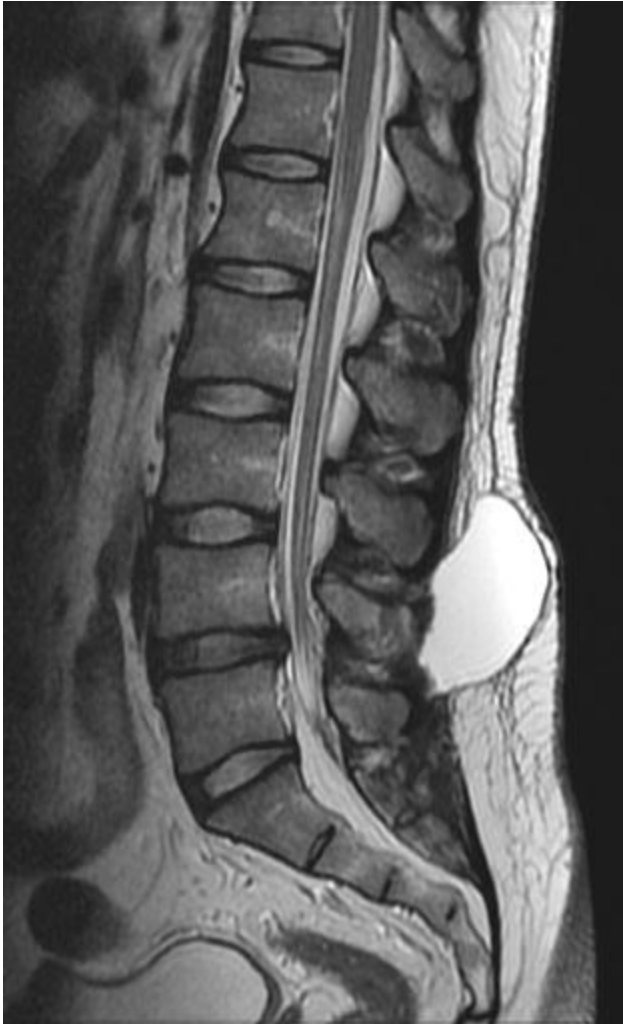**Image 2.** T2W axial image. Note the pocket of gas posterior to the thecal sac and the light colored fluid-filled pockets.



**Image 3.** T1W axial image

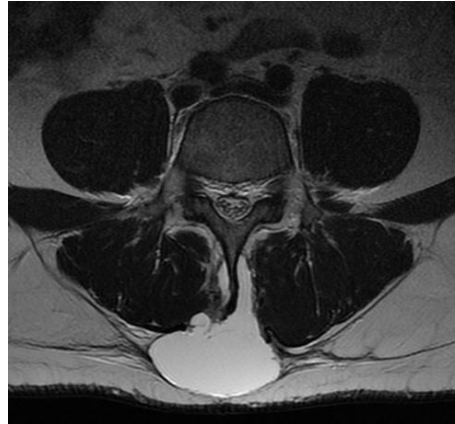These images show several radiographic images following a L5 laminectomy. The path of the surgeon is visible in all three images along with a gas pocket posterior to L5 that is dark in both T1 and T2 weighted images. Fluid-filled pockets are also seen posterior to L5. These pockets are dark on T1 weighted images and light on T2 weighted images.

## Pseudomeningocele

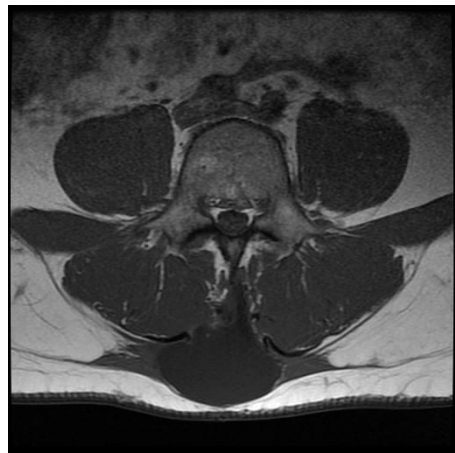

**Image 1.** This T2W sagittal image clearly reveals a post-surgical pseudomeningocele. Note the white colored pouch of fluid posterior to L4.

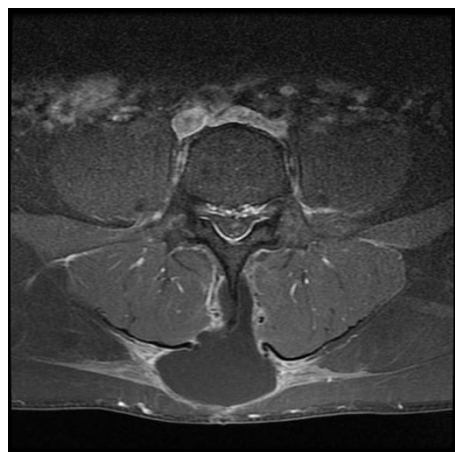
A postoperative pseudomeningocele is a complication of spine surgery. This unintended complication is essentially a pouch of cerebrospinal fluid (CSF) that has leaked into the paraspinal tissues. It appears cyst-like on MRI.



**Image 2.** T2W axial image

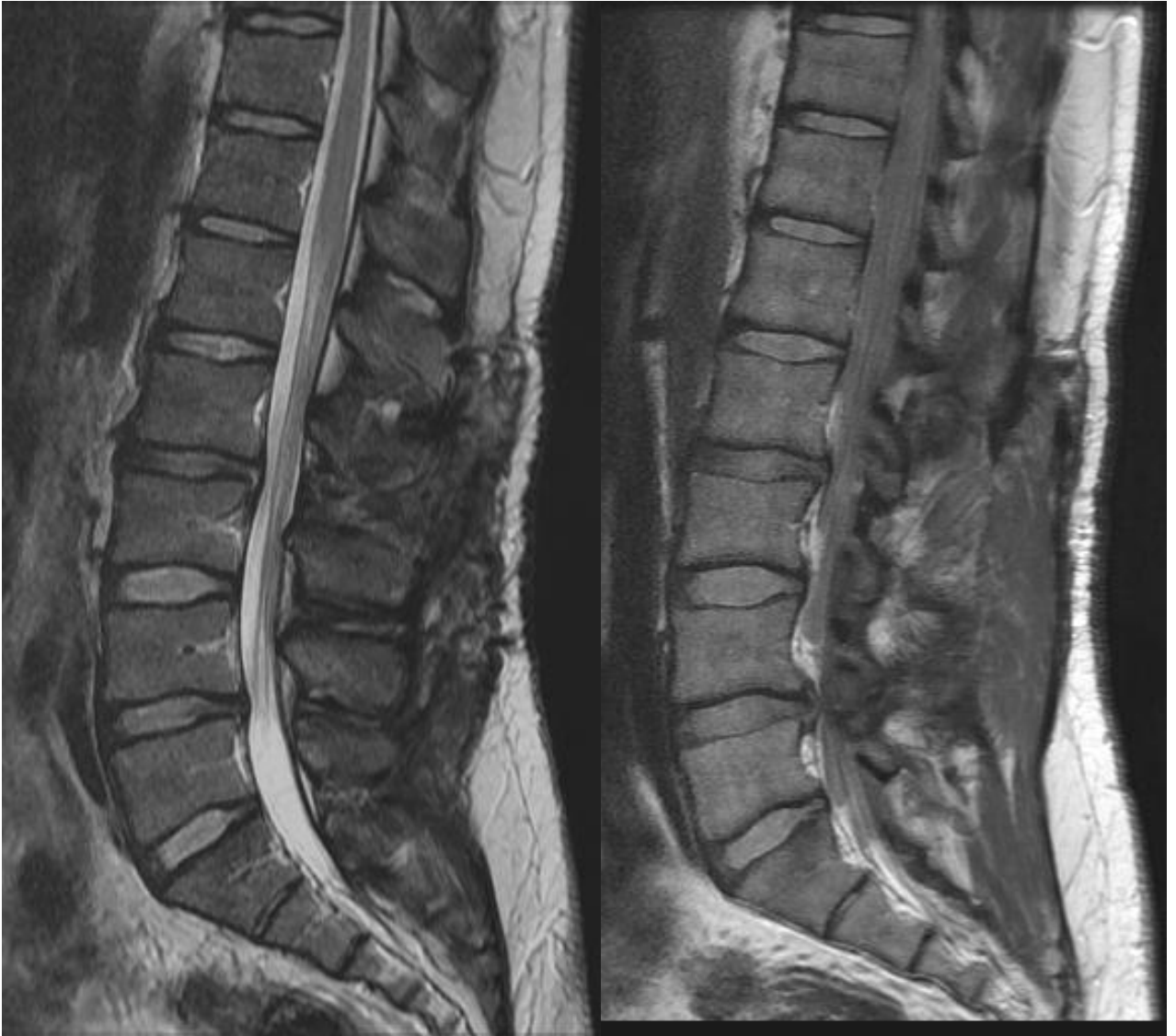

**Image 3.** T1W axial image



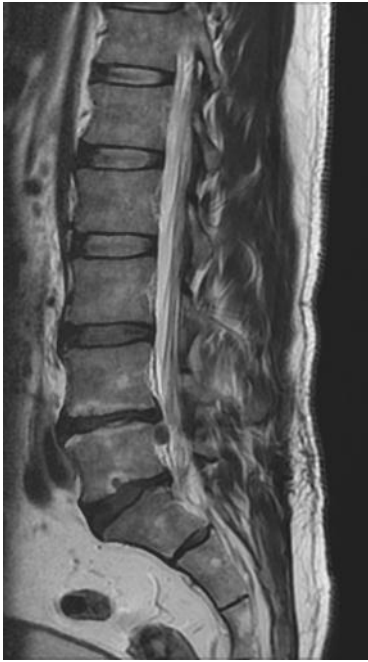**Image 4.** T1 fat saturated image

## Five level Hemilaminectomy Discectomy

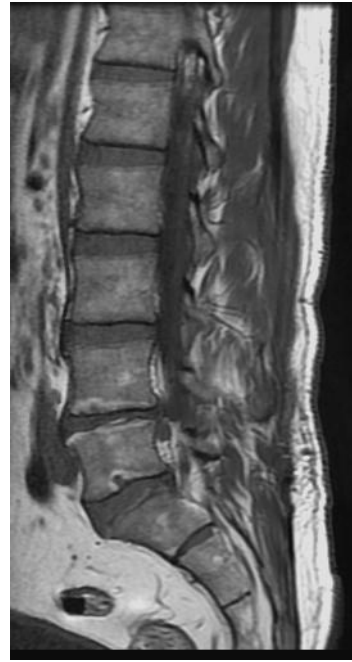

These sagittal images are of a 45 year old man who had lumbar surgery five years prior. The surgery included 5 levels of hemilaminectomy and discectomy. Note the extent of scar tissue in the soft tissues.

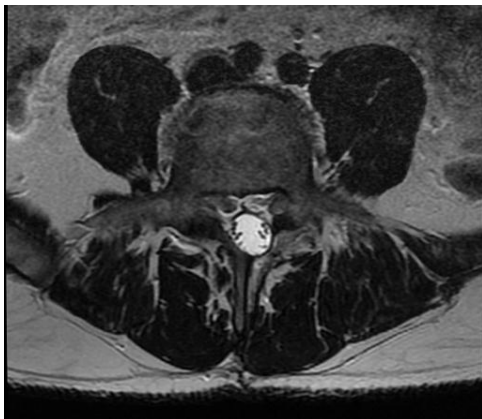
## Displacement of the Thecal Sac Through a Hemilaminectomy



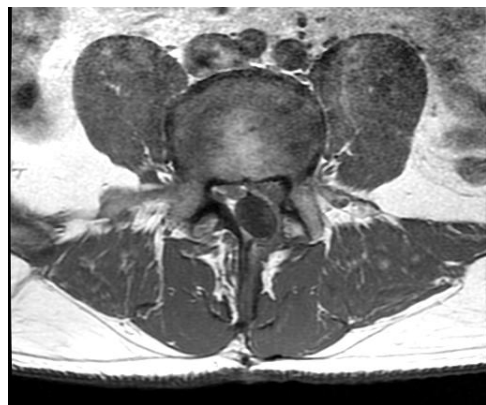**Image 1.** T2W sagittal image



**Image 1.** T1W sagittal image



**Image 3.** T2W axial image

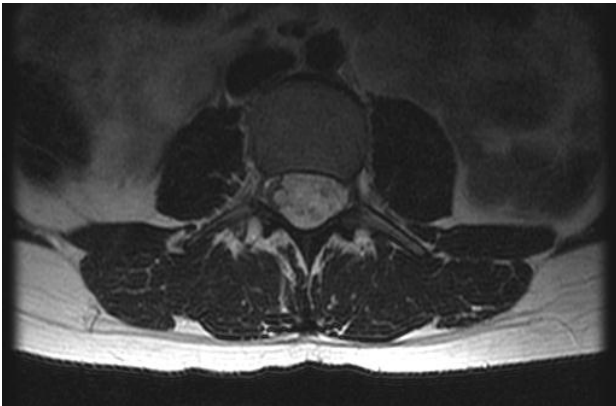


**Image 4.** T1W axial image

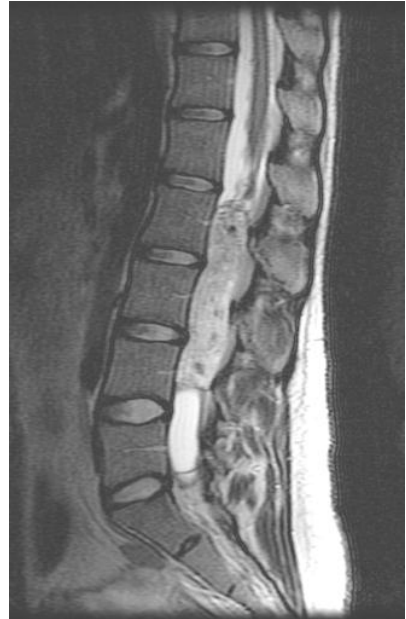This series of images shows the MRI findings of a lumbar spine after a left hemilaminectomy. The path of the surgeon is less visible on these images than those of the previous page. The axial images show the thecal sac being displaced into the gap in the posterior arch left by the hemi-laminectomy. The sagittal images reveal a sequestered disc fragment from an extrusion at L4-5.



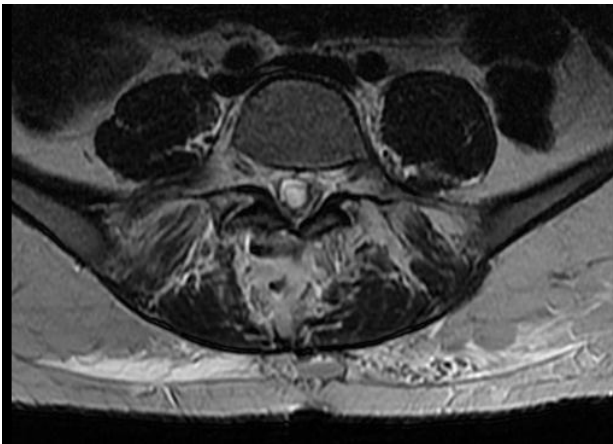
## Pre and Post Surgical Images of an Ependymoma



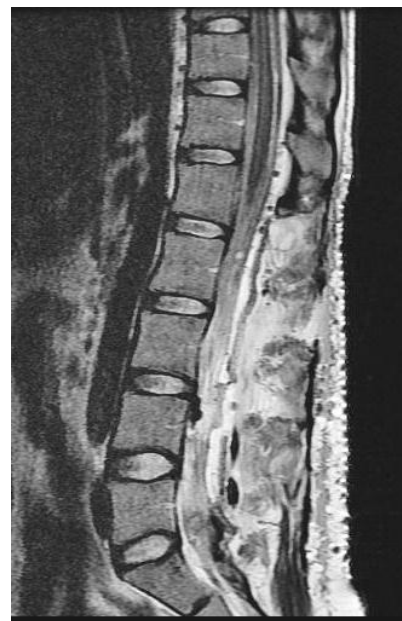
**Image 1.** T2W axial image of an ependymoma.



**Image 2.** T2W sagittal image of a large ependymoma in the central canal from L2-L4.



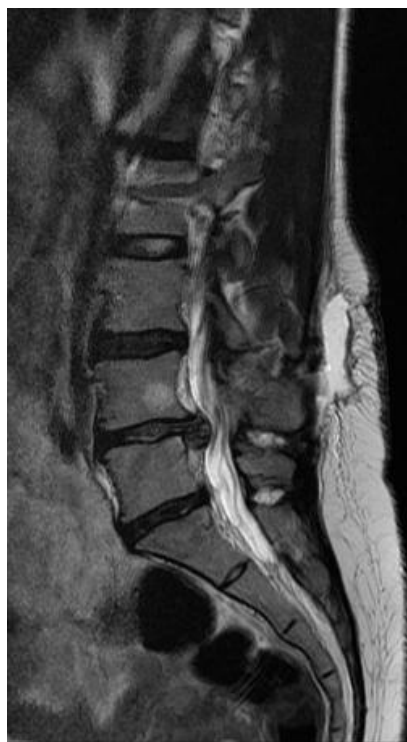**Image 3.** T2W axial image of post surgical changes.



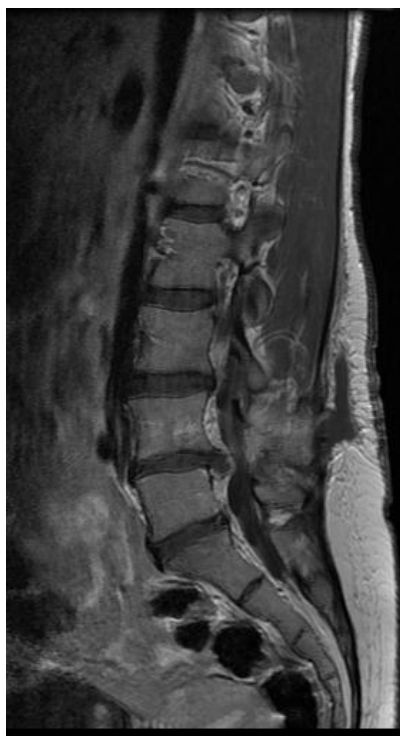**Image 4.** Post-surgical T2W sagittal image.

This series of images shows the MRI findings of a lumbar spine after a large ependymoma was removed from L2-L4. This tedious surgery caused significant disruption of the paraspinal muscles and posterior elements of the spine.

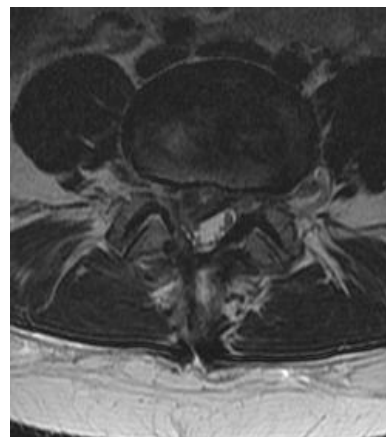
## L4-5 Re-herniation 2 Weeks After a Discectomy



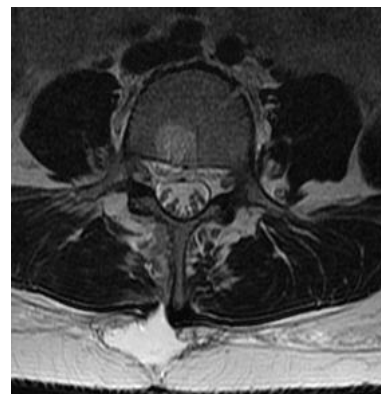
**Image 1.** T2W sagittal image of a large L4-L5 extrusion. Note the pocket of fluid posterior to the spinous processes of L3 and L4.



**Image 2.** T1W sagittal image of a large L4-L5 extrusion.



**Image 3.** T2W axial image of a large L4-L5 paracentral extrusion is shown compressing the L5 nerve root.



**Image 4.** This T2W axial image reveals the path of the surgeon and fluid accumulation in the paraspinal soft tissues.

This series of images show the MRI findings of a lumbar spine two weeks following a right discectomy. These images display a large par central re-herniation that occurred at the site of the previous surgery. *Re-herniations* at the site of surgery occur between 9-25 % <sup>1, 2, 3, 4, 5</sup>.

<sup>1</sup> Hu R, et al. A Population Based Study of Reoperations After Back Surgery. *Spine* 1997;22:2265-2271.

<sup>2</sup> Malter A., et al. 5-Year Reoperation Rates After Different Types of Lumbar Surgery. *Spine* 1998;23:814-820.

<sup>3</sup> Atlas S., et al. Surgical and Nonsurgical Management of Sciatica Secondary to Lumbar Disc Herniation: Five-Year Outcomes from the Maine Lumbar Spine Study. *Spine* 2001;26:1179-1187.

<sup>4</sup> Osterman H., et al. Risk of Multiple Reoperations After Lumbar Discectomy: A Population Based Study. *Spine* 2003;28:621-627.

<sup>5</sup> Atlas et. al. Long-Term Outcomes of Surgical and Nonsurgical Management of Sciatica to a Lumbar Herniation: 10 Year Results from the Maine Lumbar Spine Study. *Spine* 2005;30:927-935.

# Systematic Sequence of Interpretation

15

## Systematic Interpretation of the Lumbar MRI

There are several systems for systematically reviewing lumbar MRIs. This system ensures that you cover the images in a logical manner. The next two pages expand on how to analyze axial and sagittal sequences in detail. As you develop an eye for the subtleties found in lumbar MRI you will find that sticking to a systematic of observation will help you to avoid missing important findings.

### **Sequence of Systematic Interpretation of Lumbar MRI Images**

1. Verify patient identifiers and date of examination.
2. Confirm that the images and the studies are in order if using film rather than digitized images.
3. View the sagittal T2 weighted images from left to right.
4. View the sagittal T1 weighted images from left to right.
5. View and analyze the T2 weighted axial images from caudal to cephalad.
6. View and analyze the T1 weighted axial images from caudal to cephalad.
7. Review your findings and compare to the radiologist's report.
8. Determine if the radiographic findings are clinically significant or coincidental findings.
9. Integrate collaborative MRI findings into patient care.

## Sequential Analysis of Sagittal Images

1. Identify the left-right orientation. Sagittal images represent anatomic slices in a vertical plane which travel through the body from posterior to anterior and divides the body into right and left components. Scroll from left to right. If you are unable to identify the orientation of the sagittal images, remember that the aorta is on the left and that the inferior vena cava lies on the right. The aorta typically has greater girth and a more symmetrically round appearance.

2. Analyze the spine from a global view. Scan through the sagittal images and look for larger, more obvious findings:

Alignment of the spine – Spondylolisthesis and retrolisthesis can be usually be discerned on sagittal inspection. Scoliosis can be a little more difficult. On sagittal imagery a scoliosis will present with partial views of structures and a contorted view of the spinal canal and vertebral bodies.

Vertebral body shape- Identify endplate disruption, Schmorl's nodes, compression fractures, block vertebrae, and fusion.

Vertebral body content- Analyze the cortical bone for edema, tumors, fatty infiltration, and hemangiomas.

Posterior Elements- Evaluate the facets, the pars, the spinous processes, the pedicles, and the lamina.

End plates- Look for sclerotic changes and alterations in signal intensity. Also look for disruptions or fractures of the endplates.

3. Intervertebral foramina:

The IVF should be a light colored peanut-shaped image with a gray dot in the middle. The light color is due to the fat that is in the foramina. When displaced, the light colored fat will alter in shape. The gray dot in the foramina is the exiting nerve root.

4. The discs and the canal:

Look for alterations in disc height. Increased disc height may occur with discitis. Loss of disc height and reduced water content is indicative of degeneration. Disc tears and derangements may also be observed in sagittal imagery. Note disruptions of the thecal sac, the cauda equina, and nerve roots.

High intensity zones (HIZ) may be observed in T2 weighted images. These bright colored zones indicate the presence of disc tears, scarring, or vascularization of the annulus.

The cord should terminate at about the level of L1. Increased signal (brightness) on T2 weighted images may indicate cysts, tumors, syrinxes, or demyelination.

## Sequential Analysis of Axial Images

1. Identify left and right. Axial images are backwards; structures that you see on the left of an axial image represent structures found on the right of the patient.
2. Begin your analysis caudally proceeding cephalad. The sacrum will be easily recognizable. Observe the S1 nerve roots. Look for perineural (Tarlovs' cysts) which occur most commonly at the S2 and S1 nerve roots.
3. As you scroll superiorly, observe the L5-S1 disc. Note the circumferential margin of the disc and inspect it for derangement. Scroll past the disc to the L5 vertebra. Note that L5 is commonly shaped like a lemon when viewed axially. Observe the bony integrity of L5. Look for elongation of the central canal which may be indicative of a spondylolisthesis.
4. The canal should be intact and not effaced. Look for effacement or disruption of the thecal sac by discs, osteophytes, or spondylosis, or other space occupying lesions.
5. Look at the lumbar discs and evaluate for tears, herniations, nerve compression, and degeneration.
6. Identify the ligamentum flavum and look for signs of hypertrophy and subsequent stenosis.
7. Evaluate the posterior elements of the vertebrae. Look for pars defects, spina bifida, facet hypertrophy, and overall posterior ring integrity.
8. Examine the retroperitoneal space.
9. In addition to examining the spinal structures, evaluate and note the paraspinal muscles, multifidus muscles, iliopsoas muscles, the great vessels, and the kidneys.
10. After scrolling up the lumbar spine, reverse directions and descend the spine to follow the course of nerve roots. Start cephalad and scroll (if using a computer) caudally. If looking at film move from slide to slide. Follow the migration of the nerve rootlets from the cauda equina from their posterior central location to the lateral anterior portion of the thecal sac and then leaving the sac as transversing nerve roots.

## Which Radiological Studies Should You Order?

Develop a relationship with your radiologist and be willing to consult with the radiologist prior to ordering radiological studies. Explain the history and work with the radiologist to determine the best study for each patient.

|  |   |
|--|---|
| <b>Trauma</b>                              | <ul style="list-style-type: none"><li>•Plain films may be used initially to determine if there is an unstable injury or displacement</li><li>•Non-contrast CT</li><li>•MRI to evaluate cord integrity</li></ul> |
| <b>Tumors</b>                              | MRI with contrast enhancement   |
| <b>Inflammation and Vascular Disorders</b> | MRI with contrast enhancement   |
| <b>Scoliosis</b>                           | Plain-film films, unless pathology is suspected, then MRI   |
| <b>Congenital anomalies</b>                | MRI without contrast enhancement  |
| <b>Infections</b>                          | MRI with contrast enhancement   |
| <b>Nerve Root Compression</b>              | MRI   |
| <b>Spondylolisthesis</b>                   | <ul style="list-style-type: none"><li>•Plain film radiographs</li><li>•CT</li><li>•MRI if there is a need to evaluate neuronal involvement</li></ul>  |

Note: There is an inherent danger in using contrast enhancements. These risks include allergic reaction, shock, and death.

CTs are less expensive than MRI and are the medium of choice for head and neck trauma. CTs utilize significant doses of radiation and increase the risk of cancer.

William E. Morgan practices in Bethesda's National Naval Medical Center, the President's Hospital. Dr. William Morgan is also credentialed at Walter Reed Army Medical Center, Washington, DC. He serves as a consultant to various United States government executive health clinics in Washington, D.C., caring for government leaders. He has served as a consultant to the Veterans Administration and the US Army. He holds faculty appointments at Palmer Chiropractic College, New York Chiropractic College, National University of Health Science, and F Edward Hébert School of Medicine. He is the team chiropractor for the United States Naval Academy football team. A veteran of military service, he has served in Naval and Marine Corps Special Warfare units. Dr. Morgan is a 1985 graduate of Palmer College of Chiropractic-West. In addition to many other awards, he has received the American Chiropractic Association's Chiropractor of the Year Award. He has been featured on CCN.com and has been interviewed by the Washington Post.

William Morgan has written dozens of articles on integrated medicine, chiropractic, and health care. Dr. Morgan uses MRI in an integrated clinical setting on a daily basis and is well suited to share this knowledge in a practical and engaging manner.

He can be contacted through his website: [DrMorgan.info](http://DrMorgan.info)

